



# URETHRAL STRICTURE / DEFECT REVIEW CASES

**F. Soleimanzadeh MD. FEBU**

Tabriz University of Medical Sciences

Tabriz - Iran

27 YO MAN

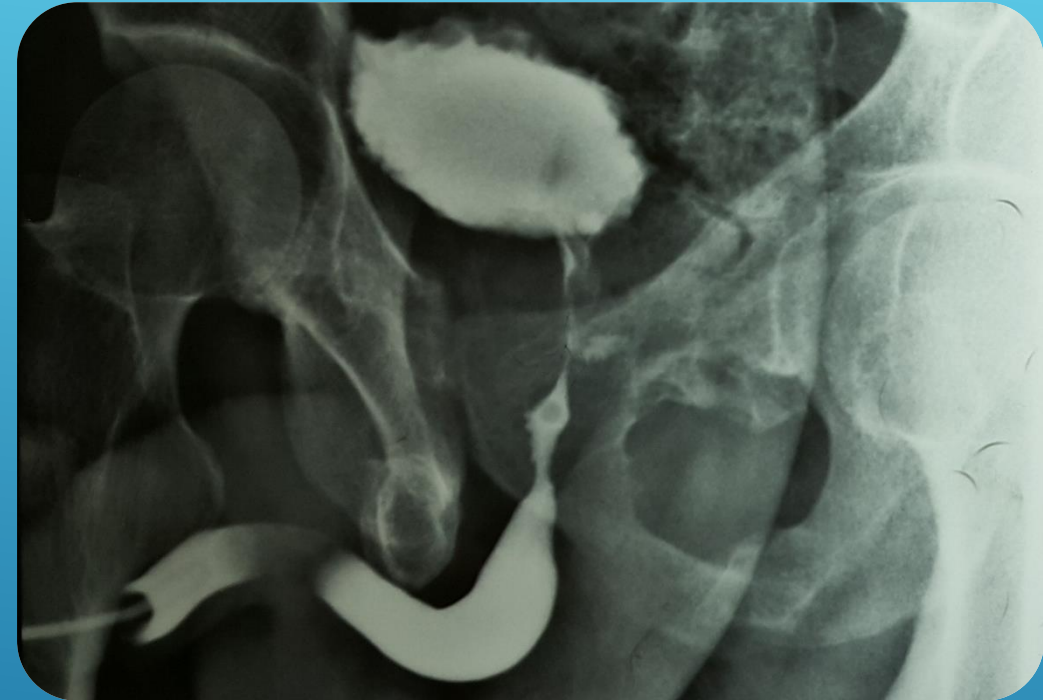POST TRAUMATIC

DVIU 4 MONTHS AGO:

RECENT RECURRENCE

**TREATMENT OPTIONS:**

- REPEAT DVIU?
- URETHROPLASTY?



STRADDLE INJURY (3 YRS)

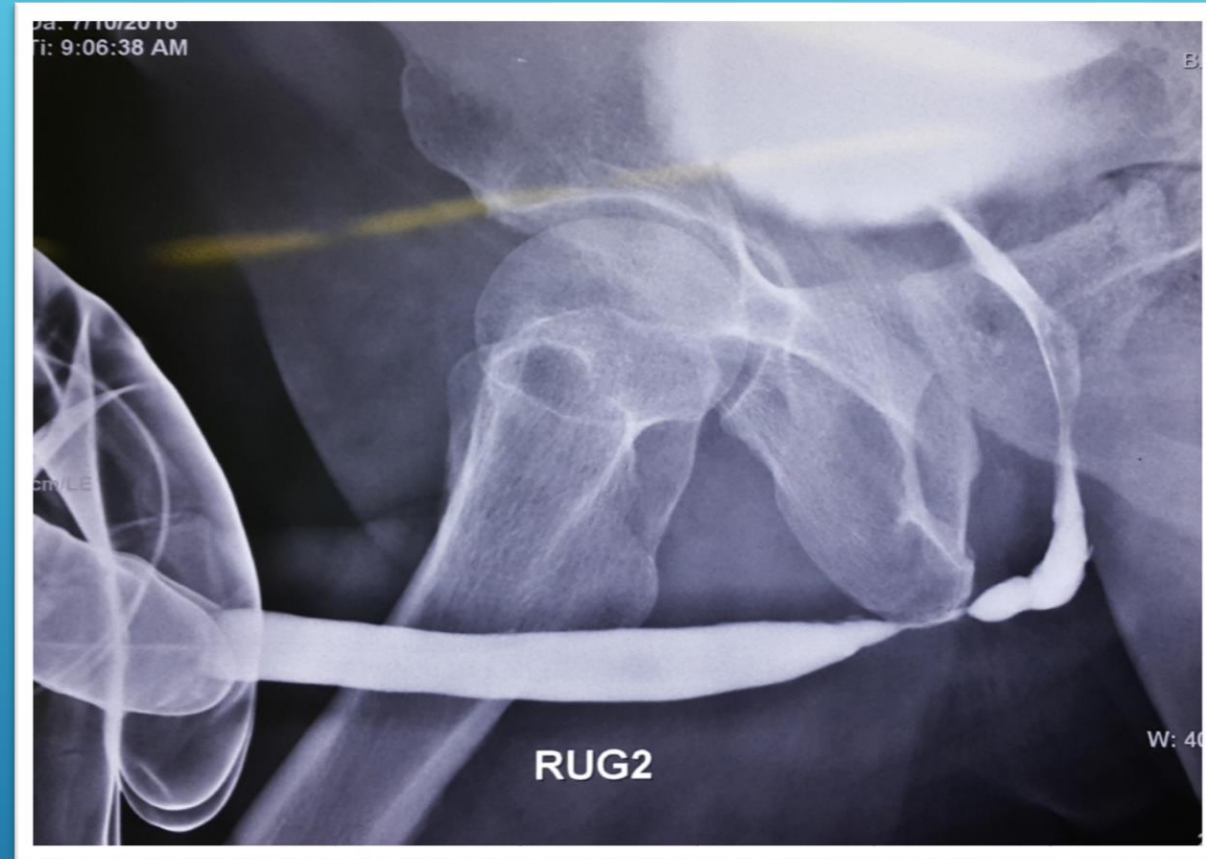
2 FAILURES OF DVIU

**TREATMENT:**

**RE – DVIU?**

**ANASTOMOSIS?**

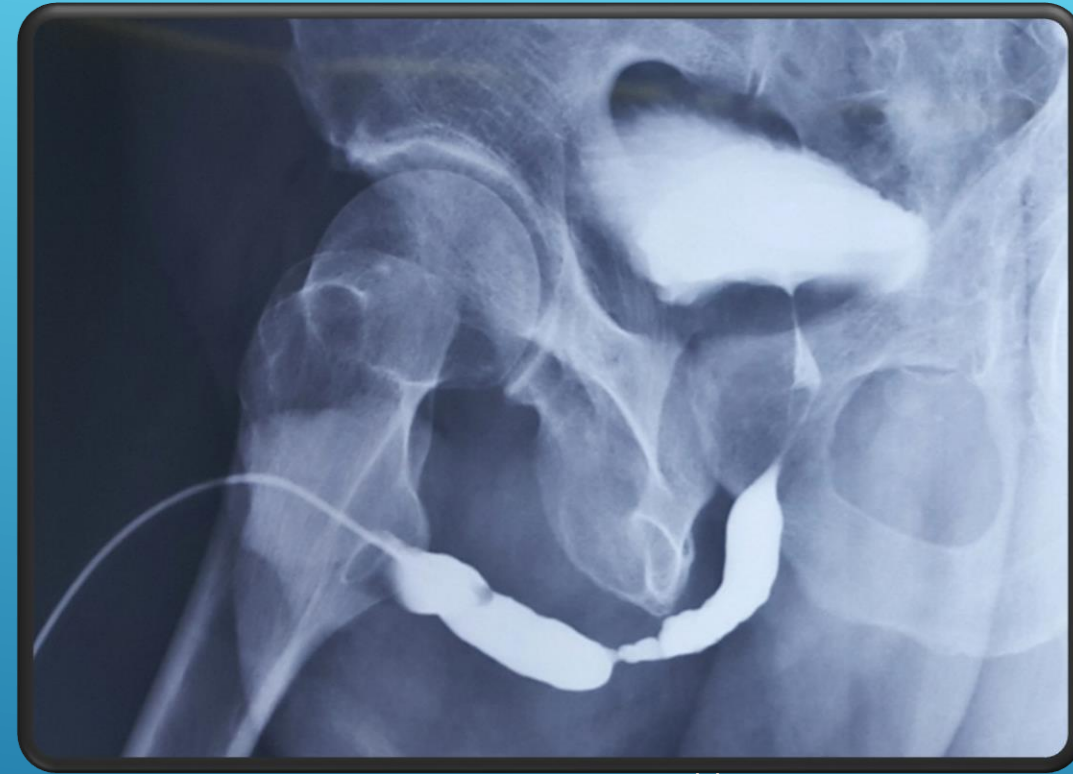**GRAFT OR FLAP?**



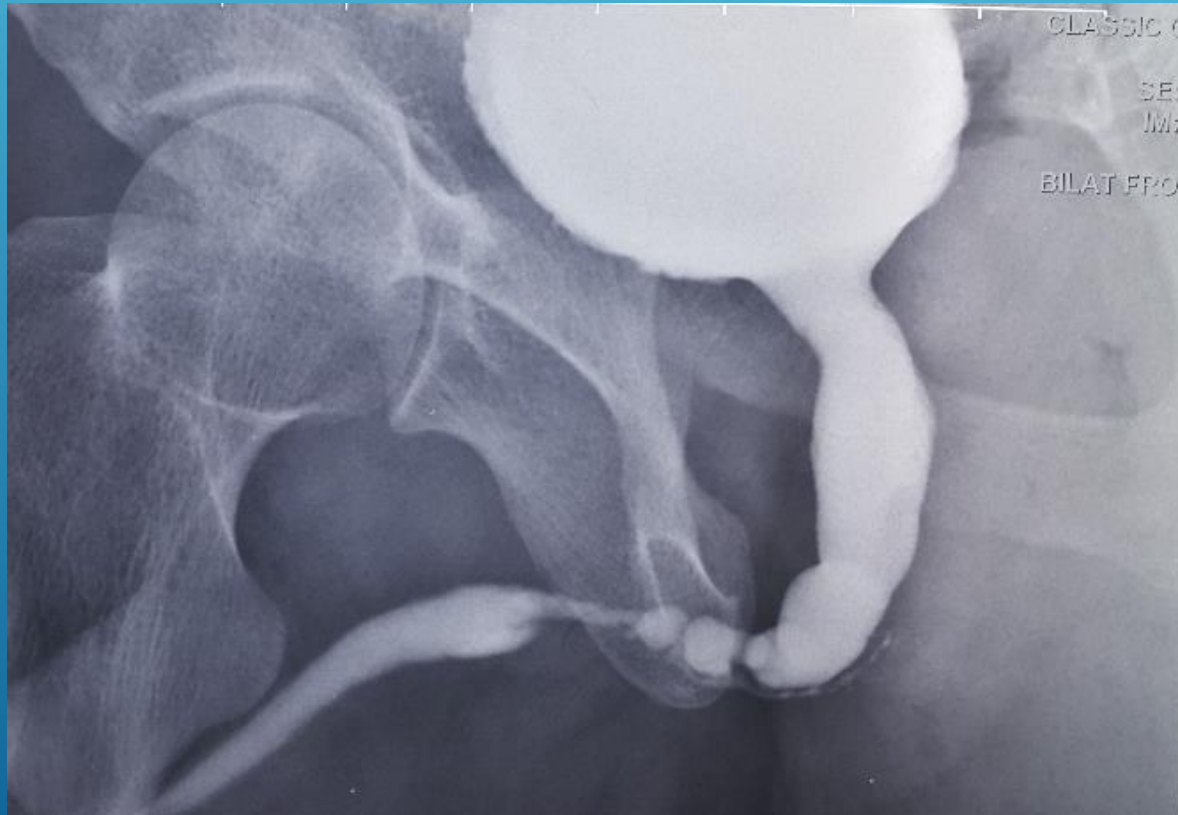
- ▶ 26 YO man
- ▶ Sport perineal trauma 2 years ago
- ▶ Recently symptomatic

## Treatment options:

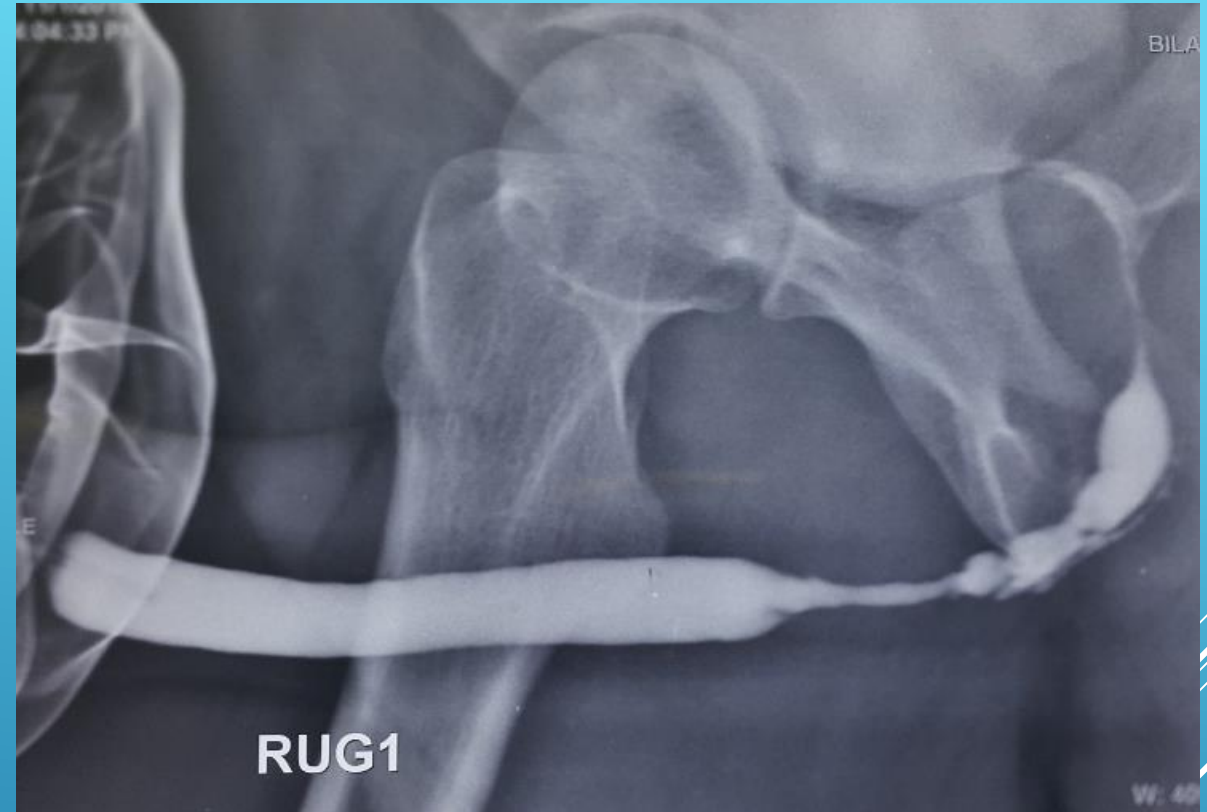
- ▶ DVIU
- ▶ End to End Anastomosis?
- ▶ Graft?
- ▶ Flap?
- ▶ .....



# What about this one?



F. Soleimanzadeh

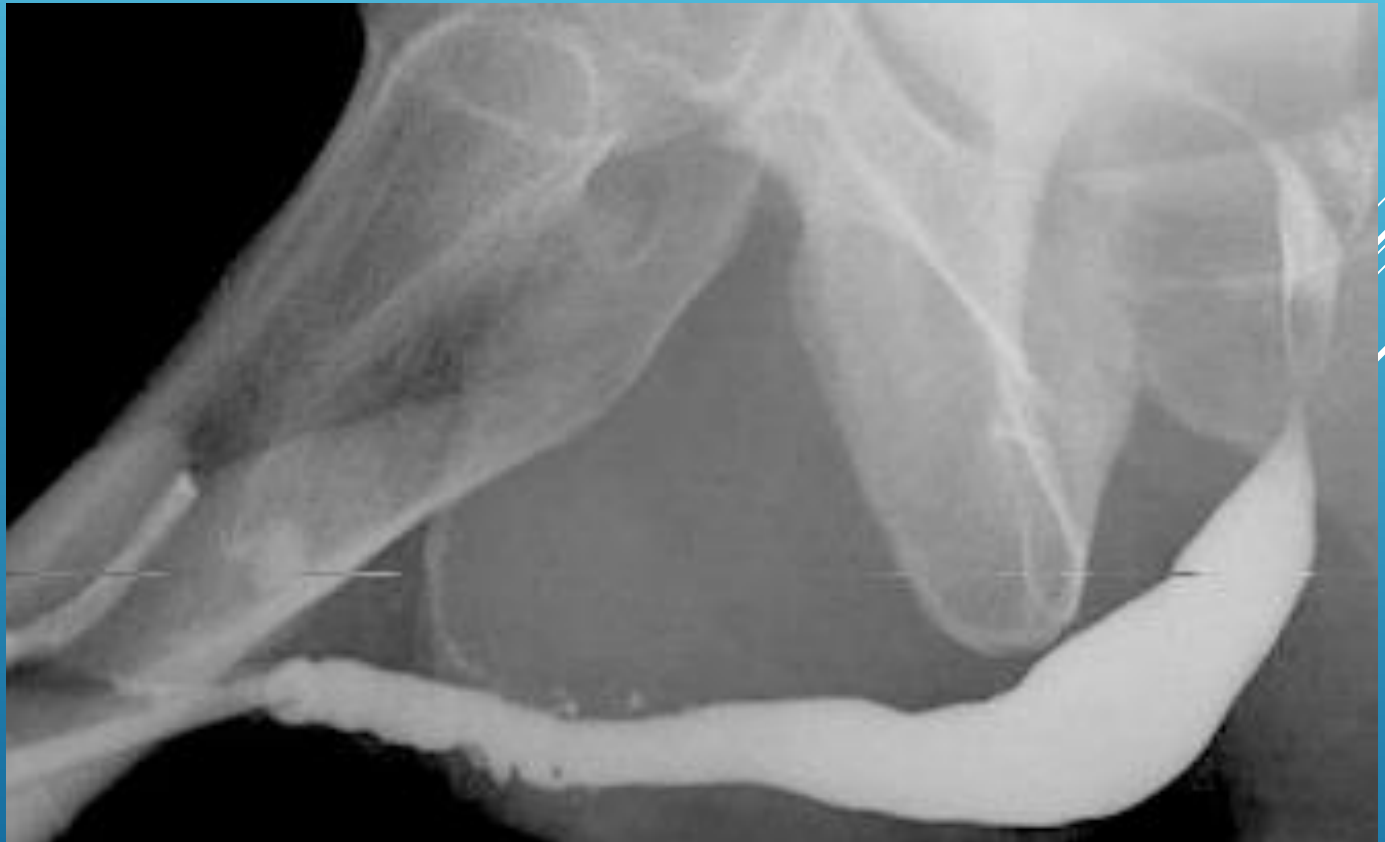

Tabriz University of Medical Science

- 46 YO man
- Meatal BXO (approved by Biopsy)
- Distal 7 centimeters of urethra involved

### Treatment Options:

- ▶ Intermittent cath?
- ▶ Graft?
- ▶ flap?



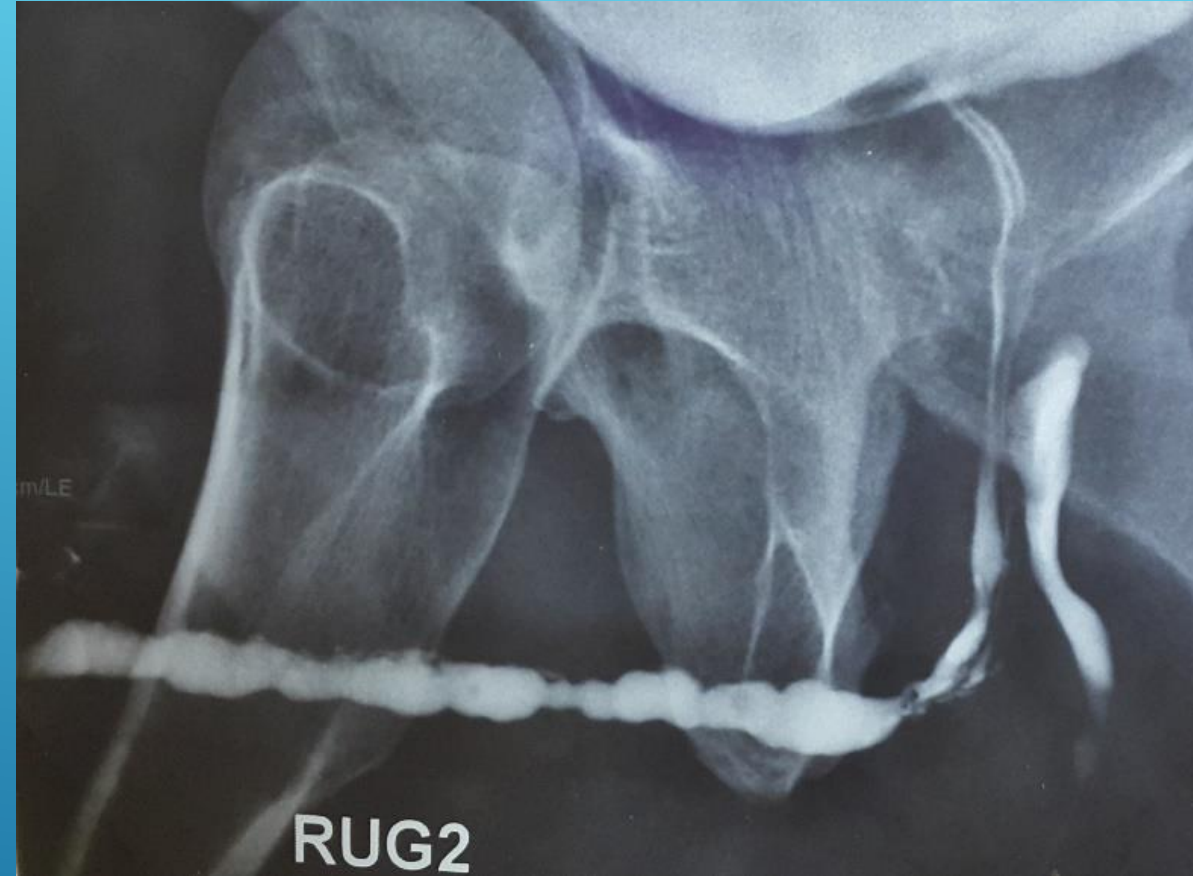
- ▶ 56 YO man
- ▶ History of brain trauma and prolonged catheterization
- ▶ Severe symptoms
- ▶ 6 French scope did not pass

## Treatment

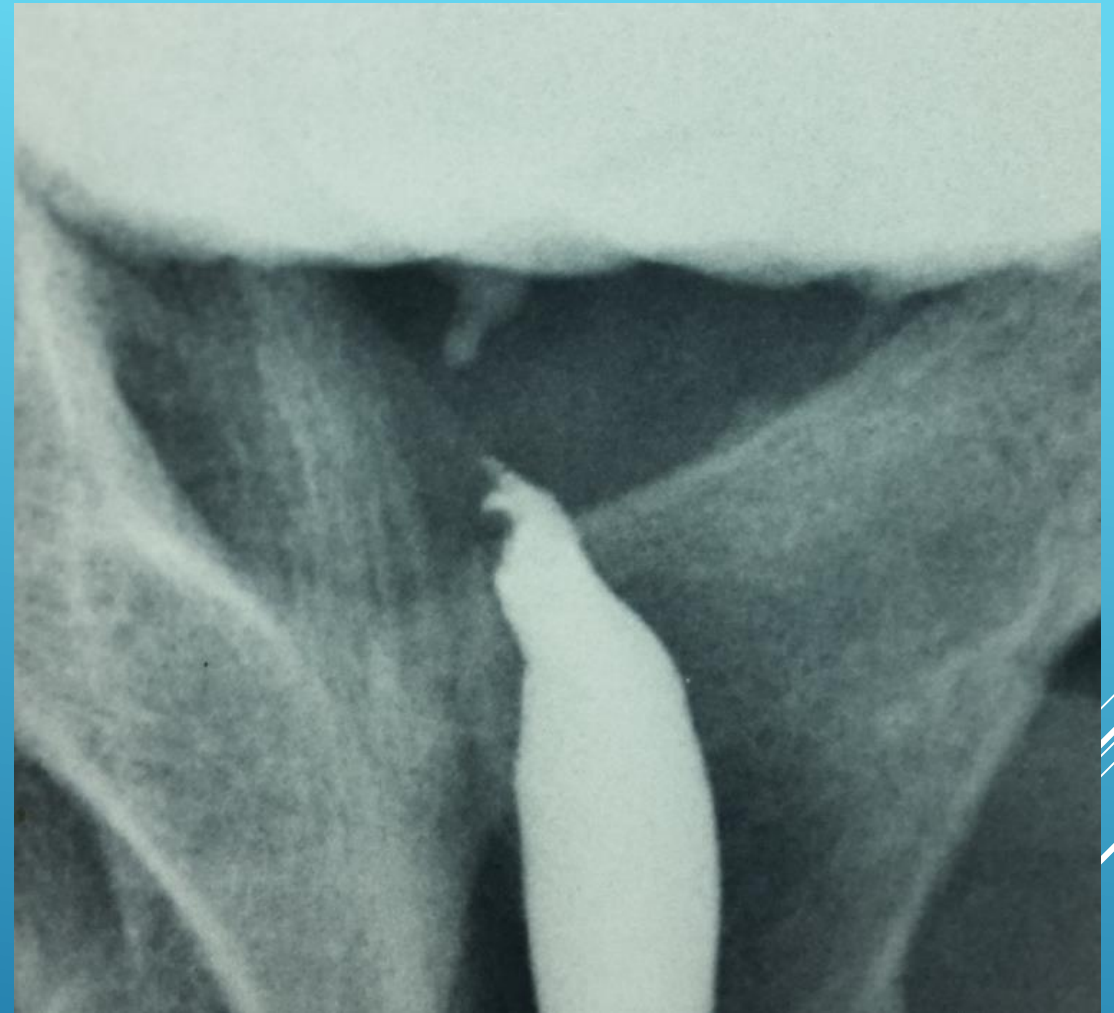
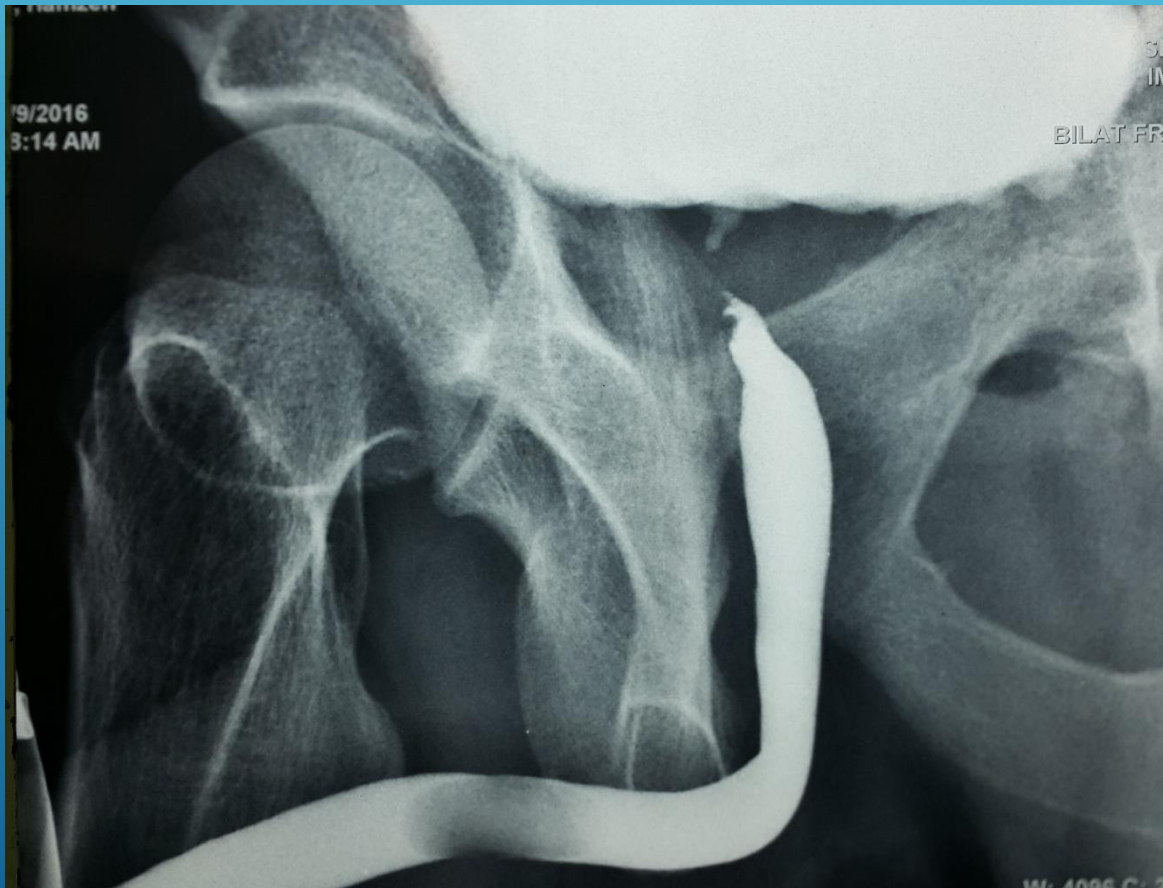
Graft Urethroplasty?

Serial and or balloon dilation?

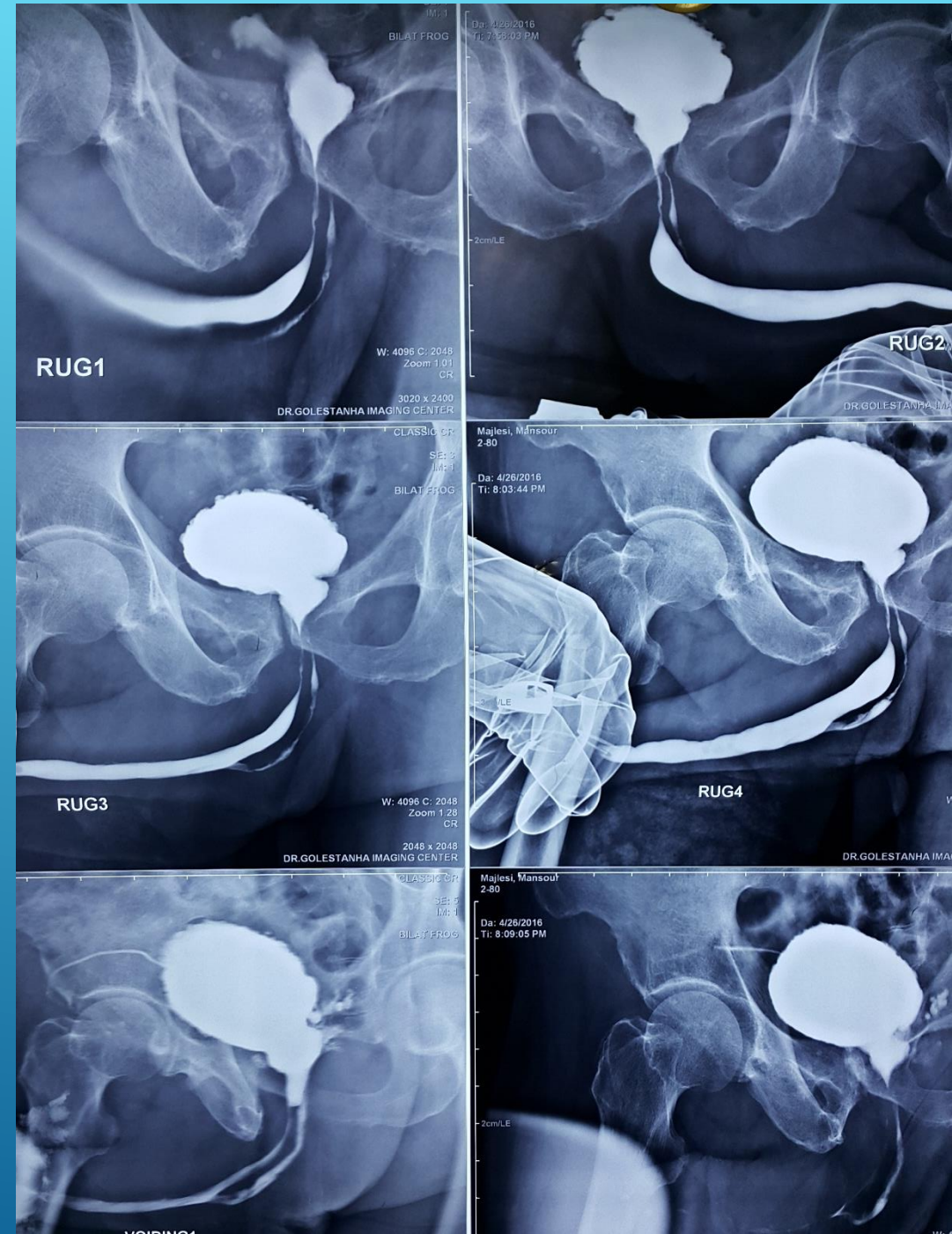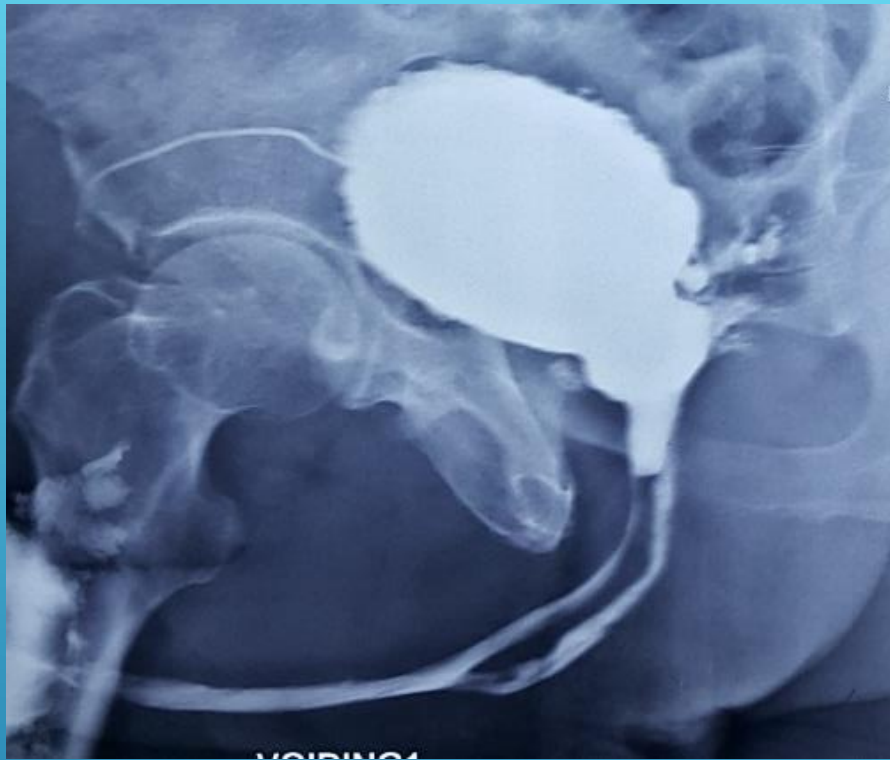Perineal urethrostomy?



# POST TURP COMPLETE OBLITERATION







**FALSE CATHETERIZATION BY  
BLIND METAL GUIDE  
2 YEARS AGO OPEN PROSTATECTOMY  
TREATMENT?**

F. Soleimanzadeh - Tabriz University of Medical Science

