

# Long Urethral Stricture in Elderly


RUD-TJH Experiences

**Jalil Hosseini**

Professor of Urology  
Reconstructive Urology Dept.  
Tajrish Hospital, Tehran – Iran

**President, A-P SRUAS**  
**Past President, UAA**

**Honorary Member, EAU**  
**Past President, IUA**



# Reconstructive Urology Shahid Beheshti Medical University

**SBMU**

**TAJRISH HOSPITAL**

**FOUNDED IN 1958**

**RUD, TAJRISH**

**24 years experience**

# Long Urethral Stricture in Elderly

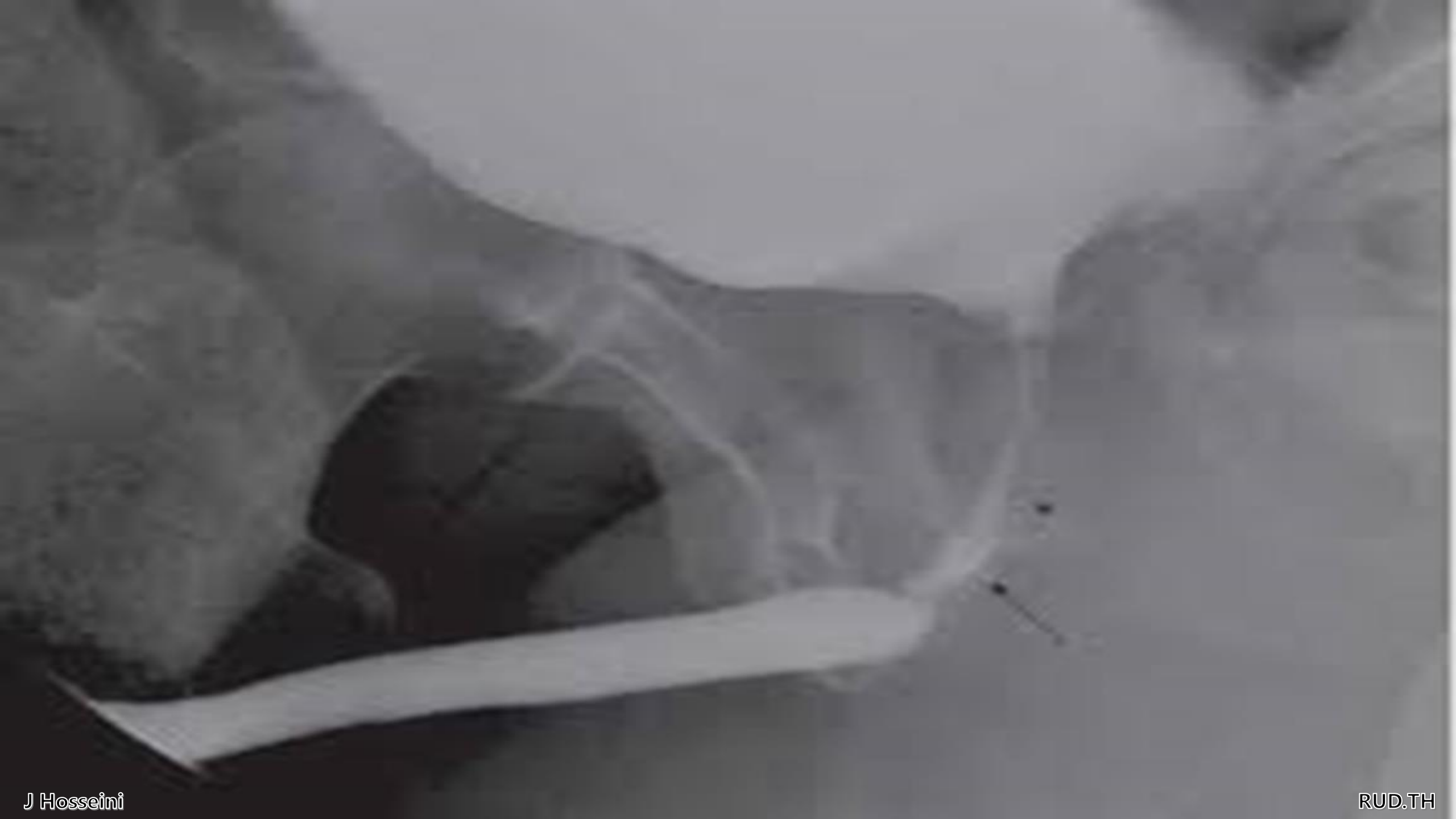- **History:**

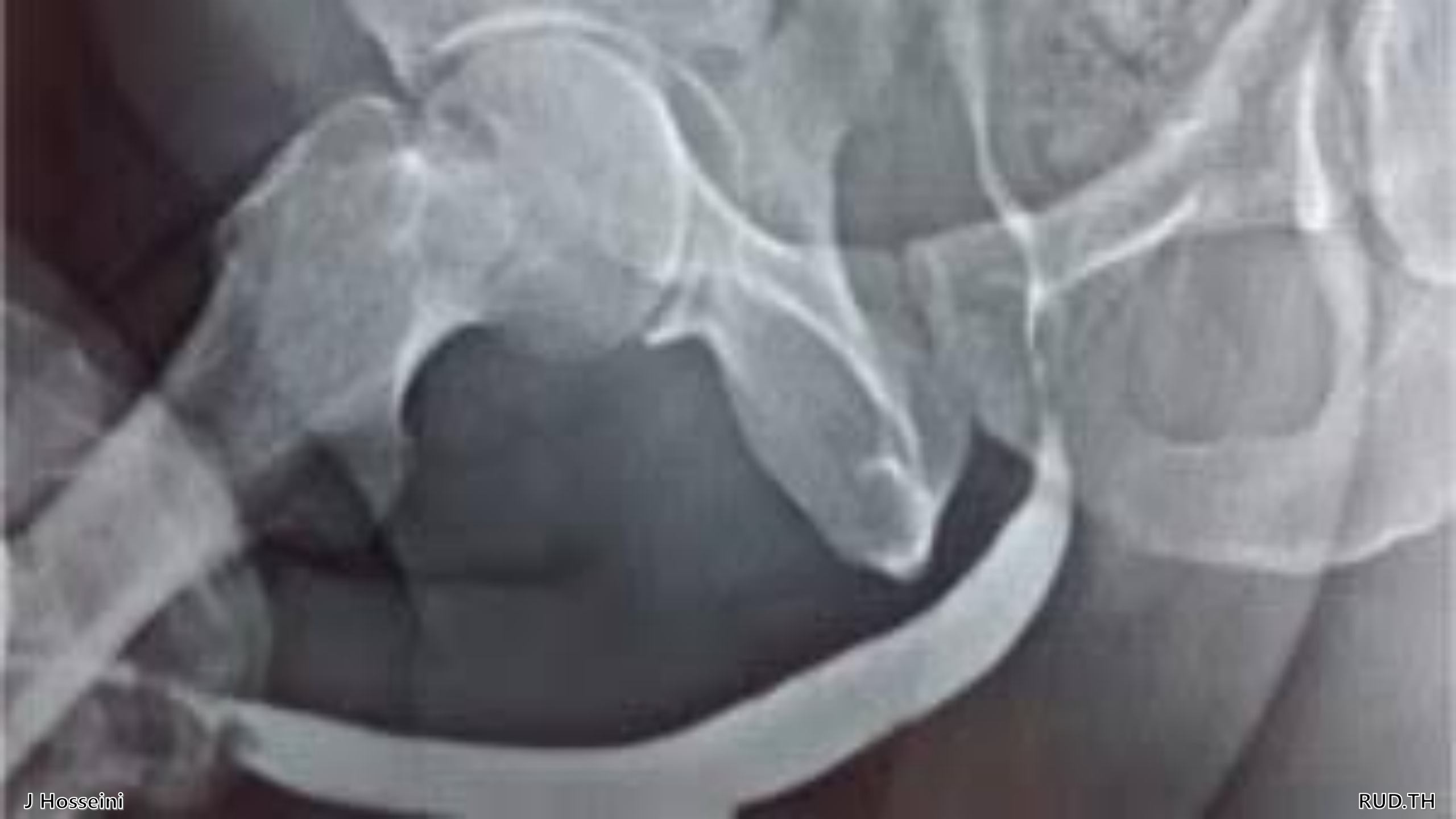- **90 years Old,**
- **Long anterior U.Stricture**
- **Several Dilatation, Comorbid**
- **Every 3 month in Operation Room with Anesthesia**

# Long Urethral Stricture in Elderly

- **History :**

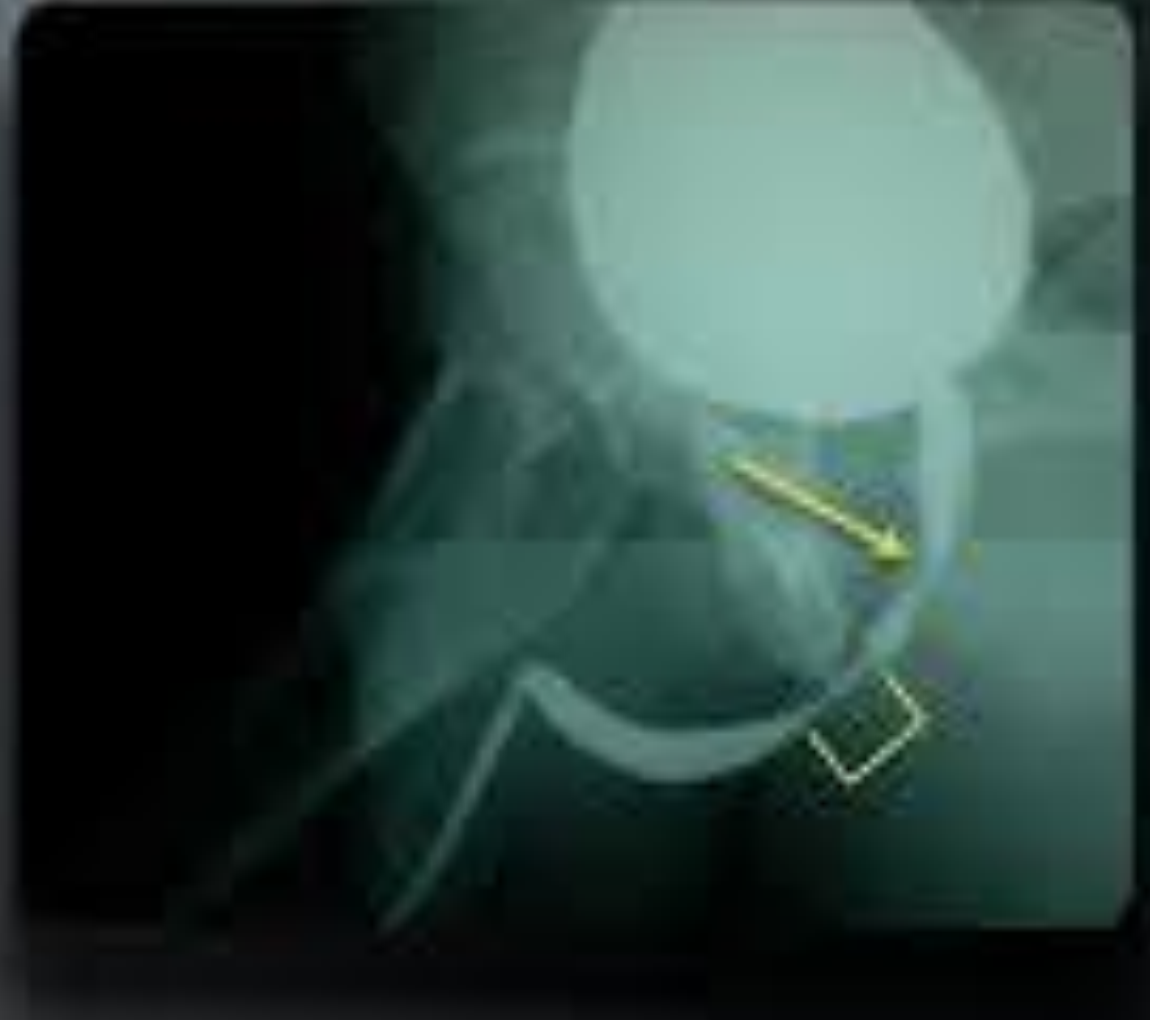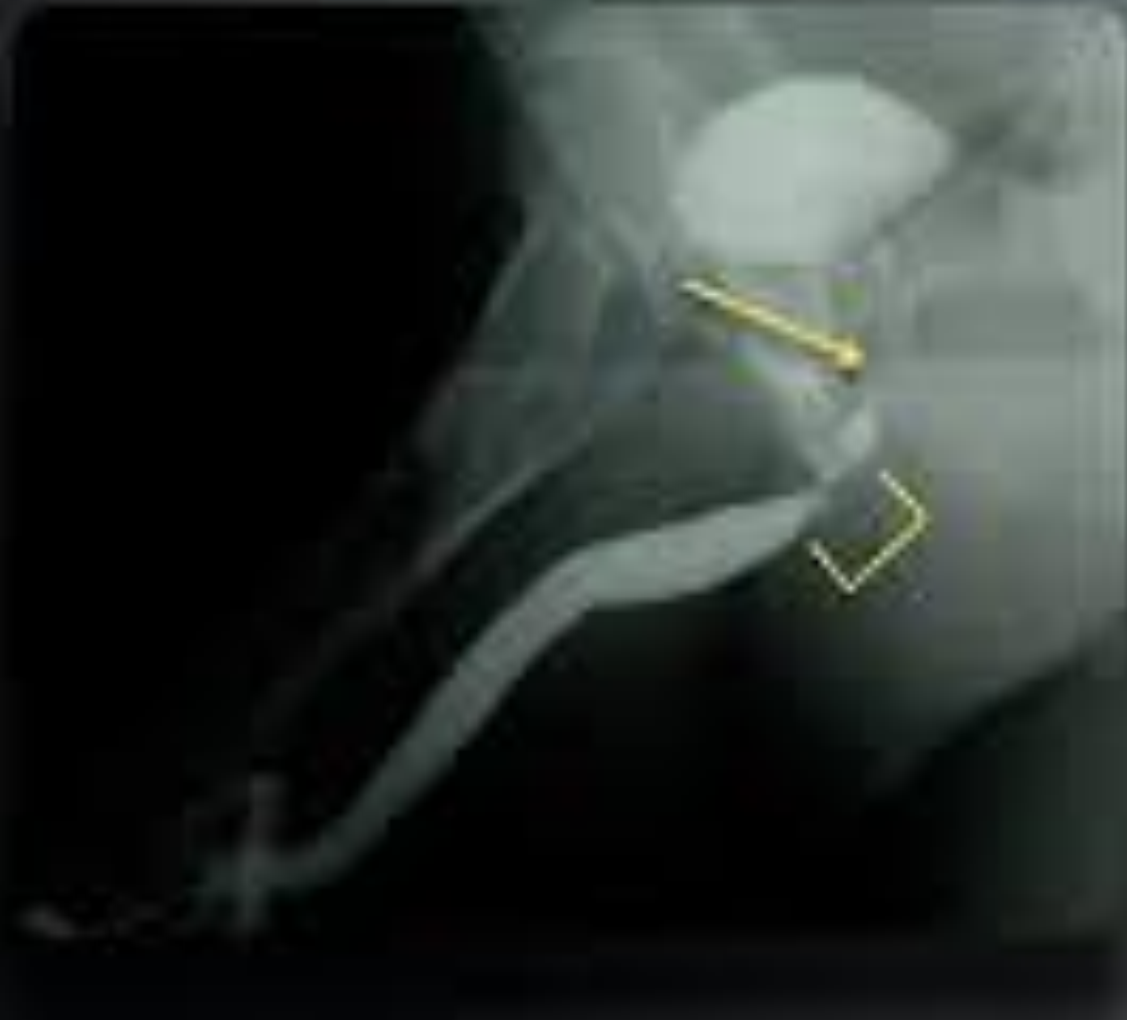- **85 Years Old**
- **Prostatectomy(or TURP)**
- **Membranous Stricture**
- **Several Dilatation**
- **Every 2 month in Operation Room with Anesthesia**





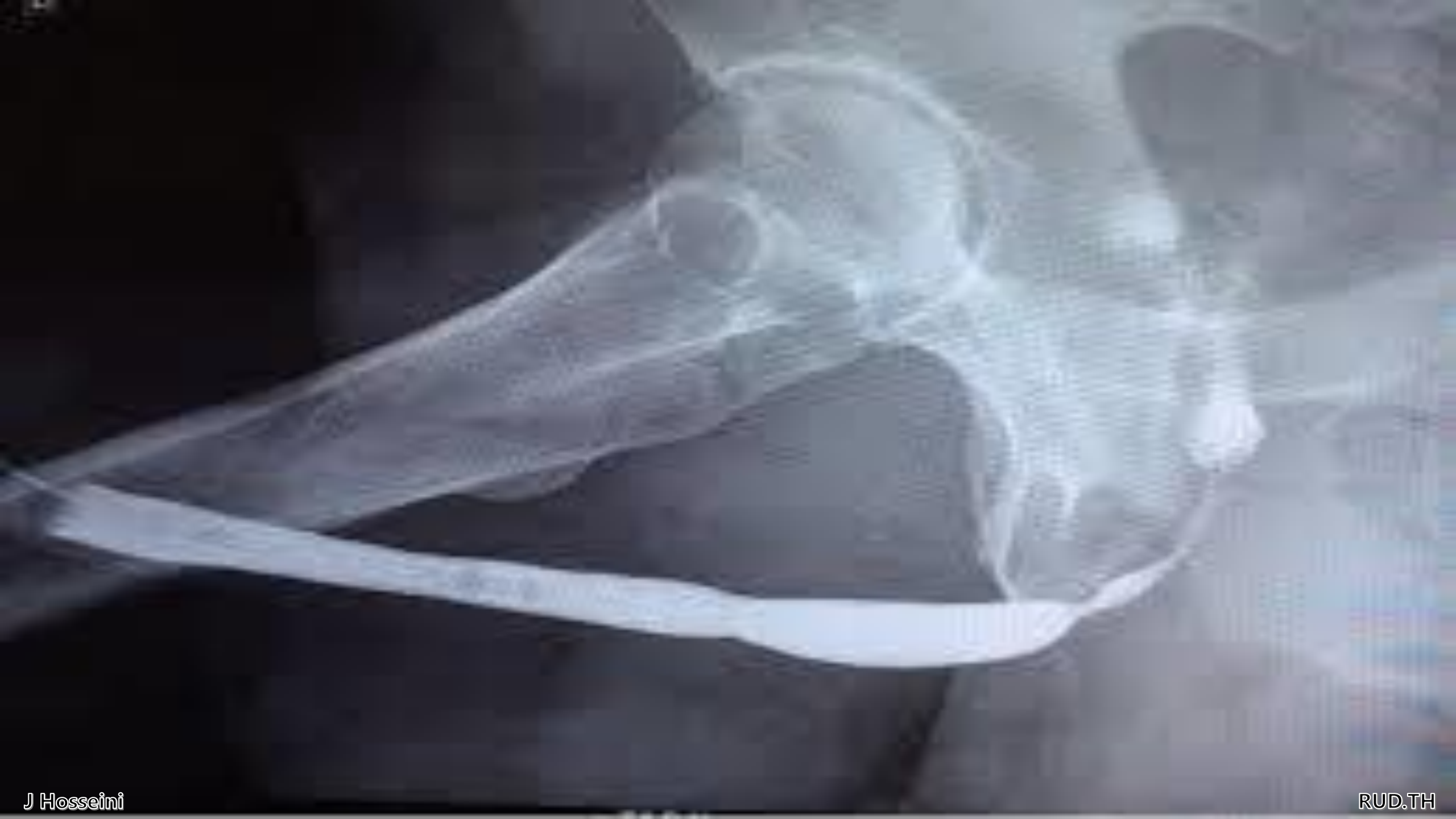Recurrent membranous  
stricture after radiation

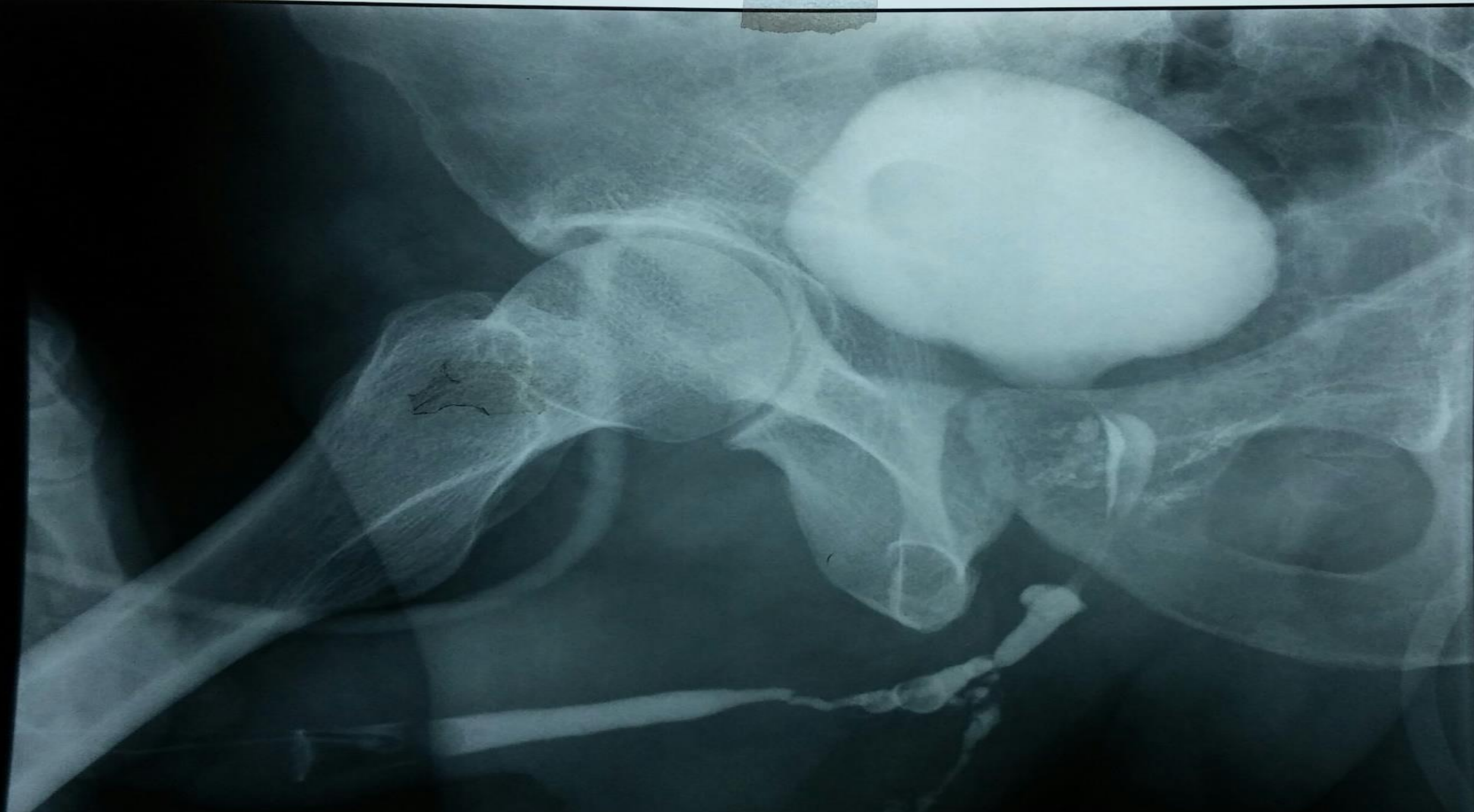



**Bulbar and Membranous Stricture**







Kushki, Tahmas  
8/38

Da: 10/24/2012  
Ti: 3:36:58 PM

CLASSIC CR

SE: 1  
IM: 1

BILAT FROG

2cm/LE

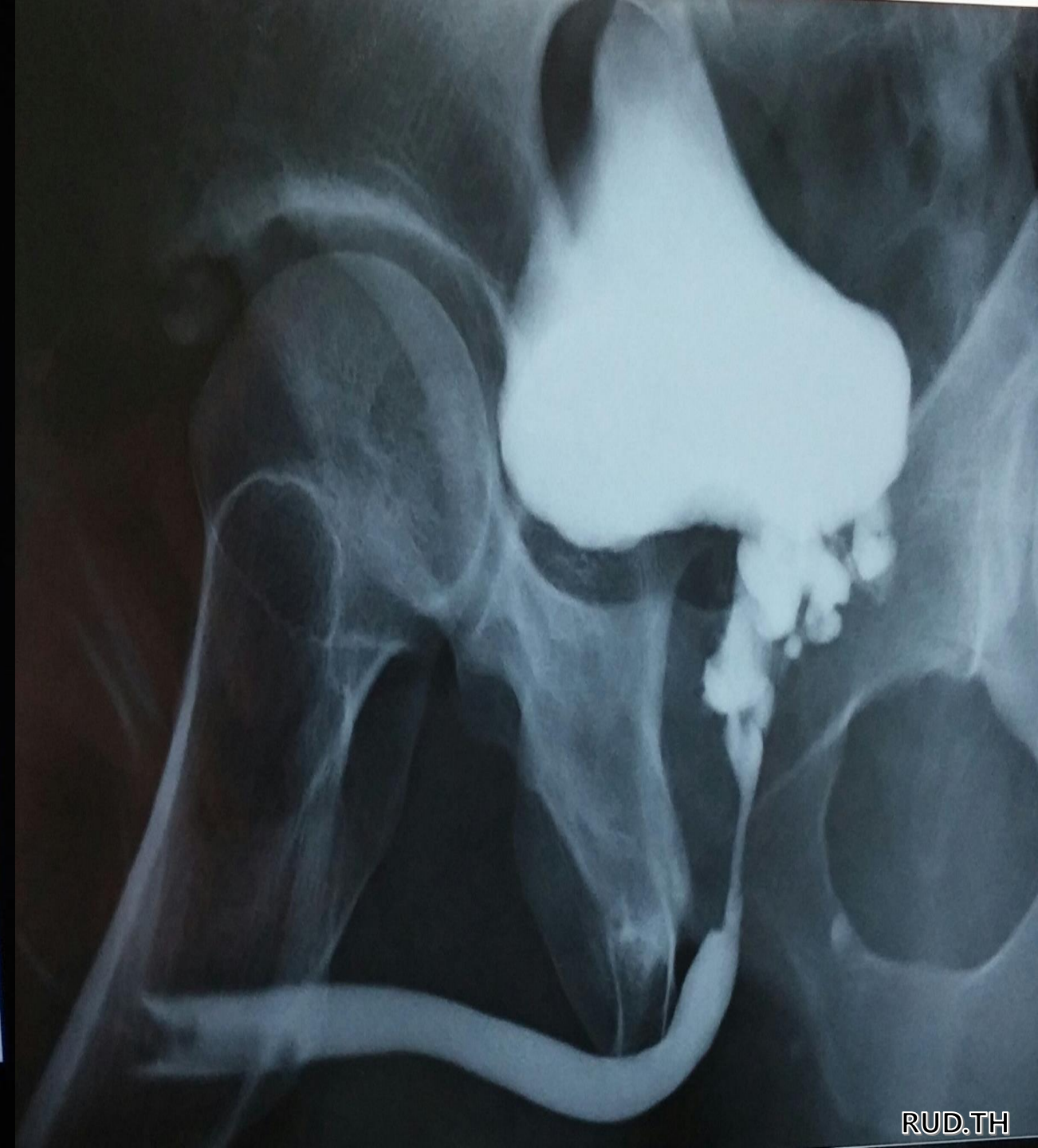
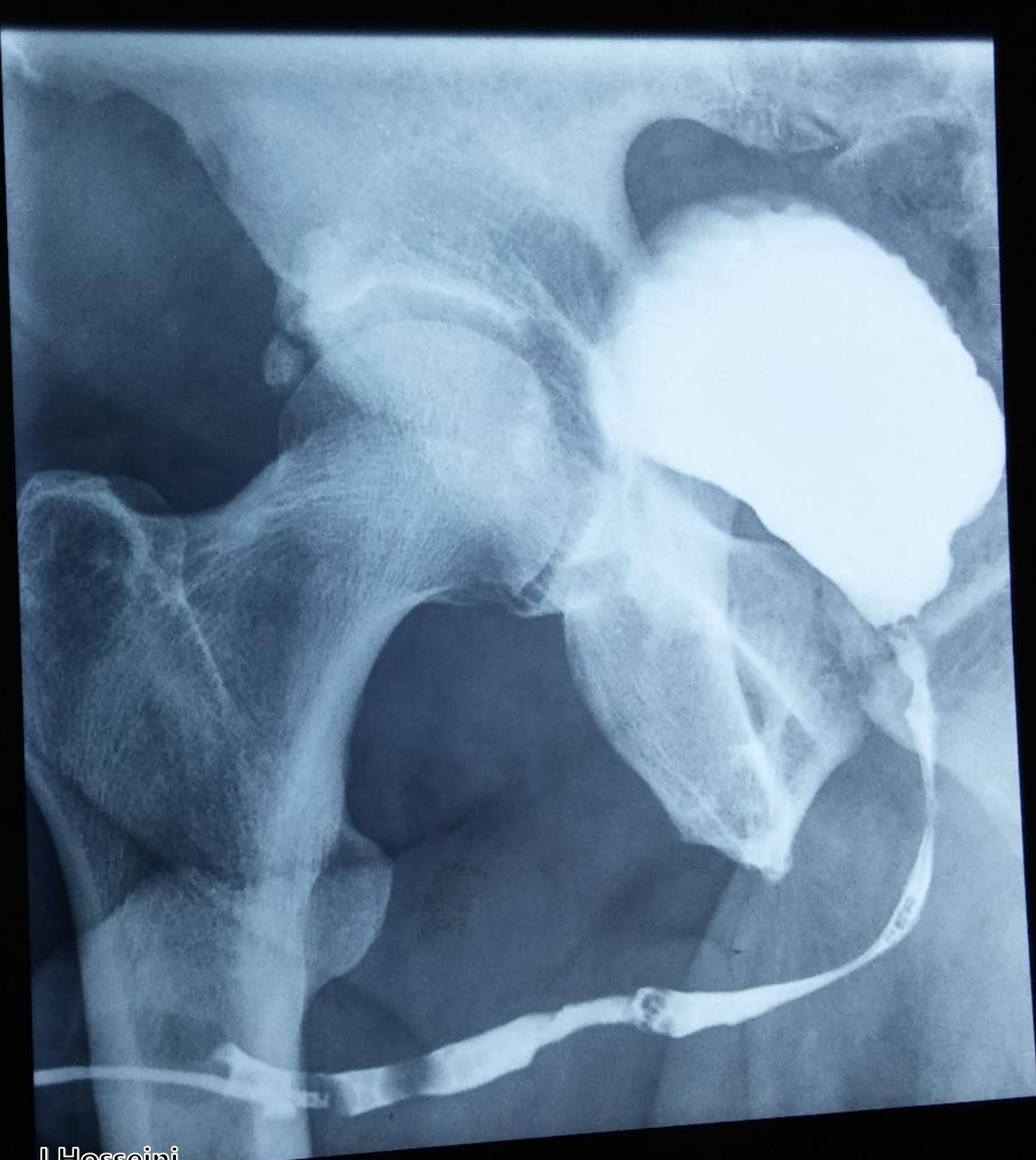
RUG1

W: 4096 C: 2048  
Zoom 1.19  
CR

3020 x 2400

DR.GOLESTANHA IMAGING CENTER RUD.TH

J Hosseini




W: 4096 C: 2048  
Zoom 1.24  
CR  
2048 x 2048  
DR.GOLESTANHA IMAGING CENTER



RUG2

W: 4096 C: 2048  
Zoom 1.09  
CR  
2048 x 2048  
DR.GOLESTANHA IMAGING CENTER



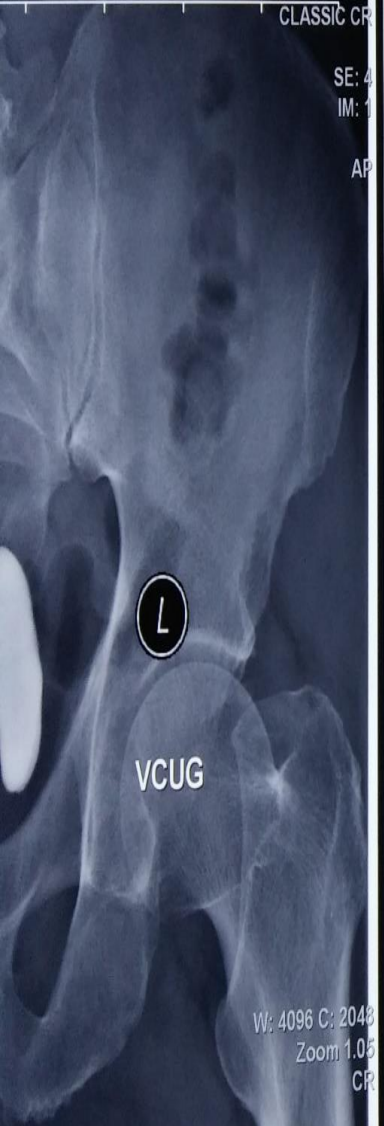
Kushki, Tahmas  
8/38  
Date: 10/24/2012  
Time: 3:42:13 PM

RUG3

DR.GOLESTANHA IMAGING CENTER  
CLASSIC CR  
SE:  
IM:  
BILAT FRO

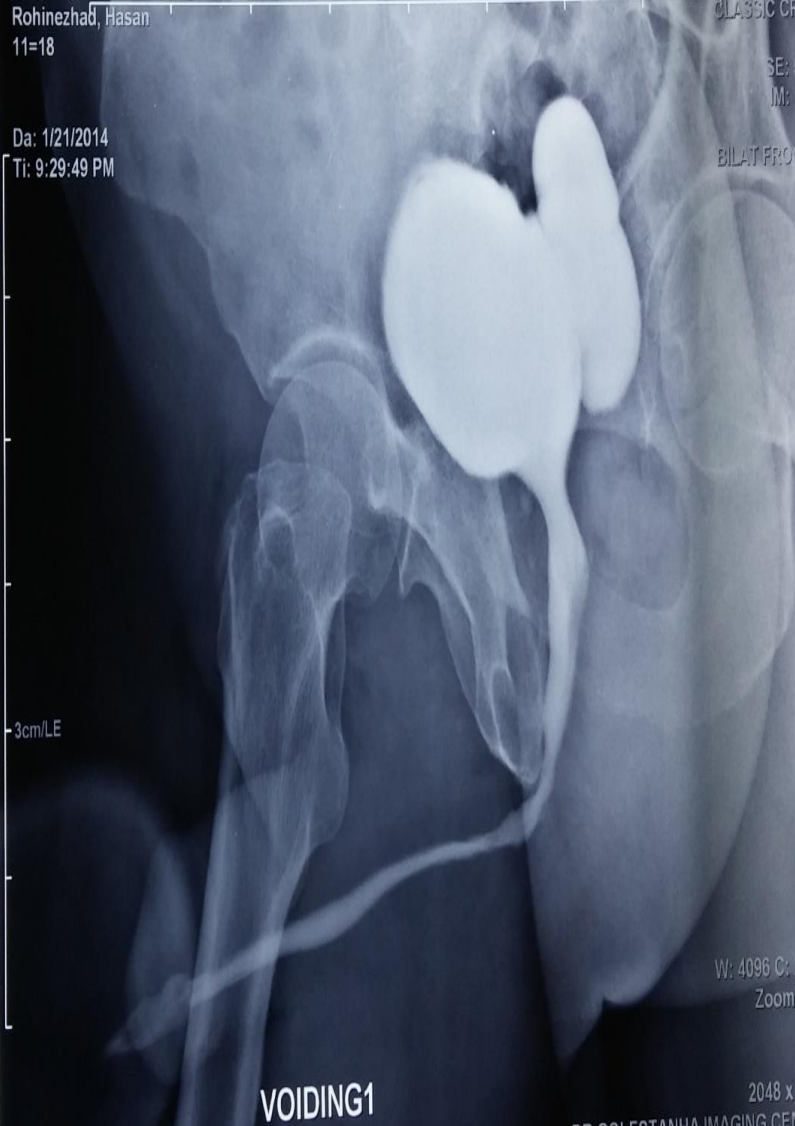CLASSIC CR  
SE: 4  
IM: 1  
AP

Rohinezhad, Hasan  
11=18  
Da: 1/21/2014  
Ti: 9:29:49 PM



L

VCUG

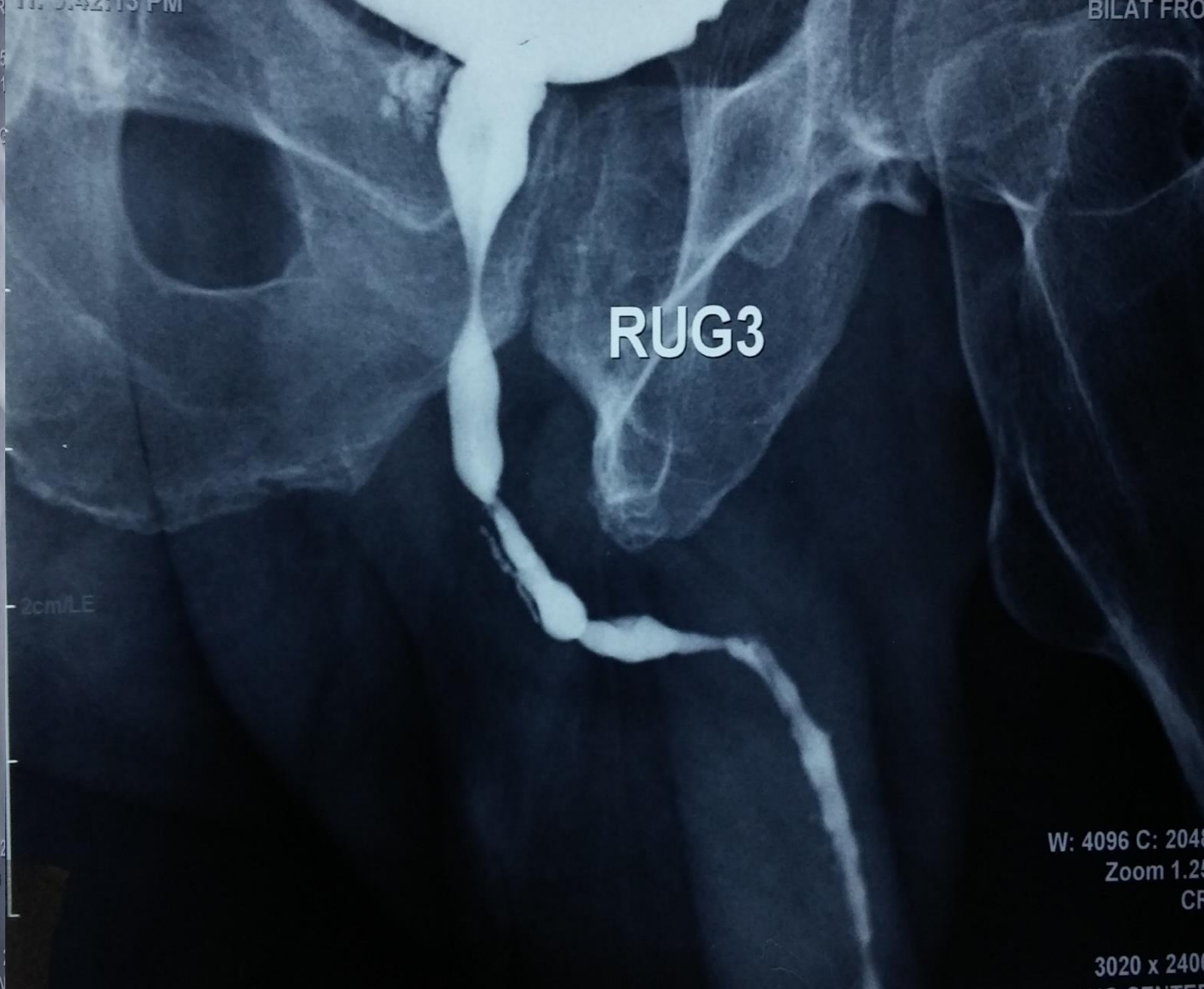


3cm/LE

VOIDING1

CLASSIC CR  
SE: 5  
IM: 1  
BILAT FRO

W: 4096 C: 2048  
Zoom  
2048 x 2048  
DR.GOLESTANHA IMAGING CENTER



2cm/LE

W: 4096 C: 2048  
Zoom 1.24  
CR  
3020 x 2400  
DR.GOLESTANHA IMAGING CENTER

J Hosseini  
2048 x 2500  
DR.GOLESTANHA IMAGING CENTER

DR.GOLESTANHA IMAGING CENTER  
RUD.TH

# Long Urethral Stricture in Elderly

- **History :**

- 85 Years old    90 Years Old .....

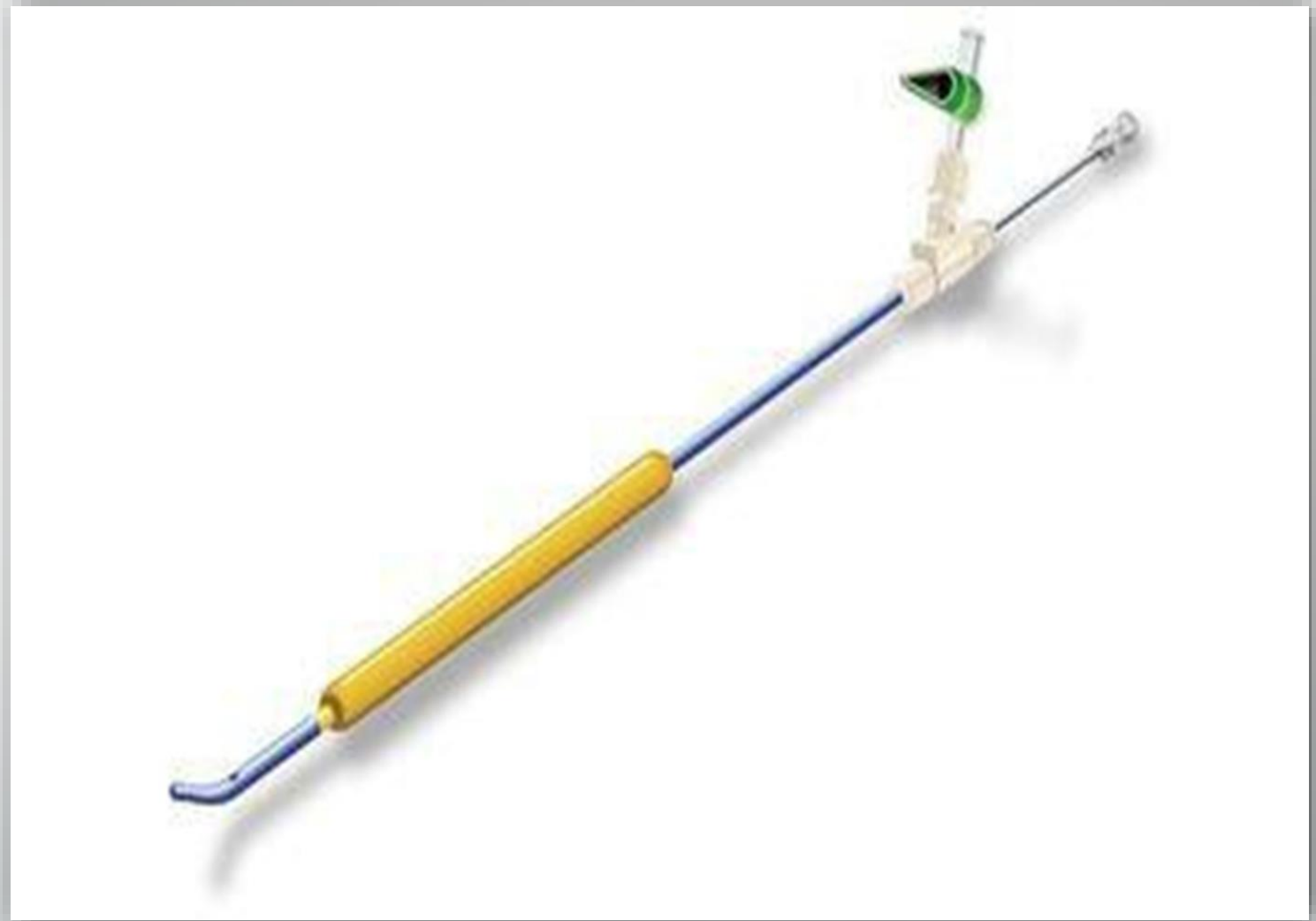
- Many operation room admit

- **How many time do you want to repeat**

# Hydraulic Urethral Dilatation

- One of the effective therapies for urethral stenosis is the use of a urethral hydraulic catheter.
- In order to take advantage of the optimal and appropriate therapeutic response
- With proper use of this catheter, the patient will not require frequent intraoperative delivery, anesthetic tolerance and recurrent dilation.
- The patients need Primary urethral dilatation to accommodate HUD
- Primary education is done at the clinic in the presence of the urologist

# HUD catheter





## Technical Points

First, remove the catheter from the compartment and clean it with a sterile serum.

- Before inserting the catheter, it is important to use the lubricants

- The catheter should be inserted into the urethra with its tilting upwards and note that the entire yellow part of the catheter is inside the urethra.
- It is recommended to use distilled water to fill the balloon around the catheter and fill the balloon to the extent that the patient feels pain (4 to 8 cc).
- Depending on the urologist's advice, the duration of the catheter in the urethra will be between 4 and 6 hours.
- After using the catheter, the catheter is thoroughly washed with a clean wash, sterilized in a sterile cleanser and kept in a container in which a single formalin tablet is inserted.  
.
- At the time of re-use with the prescribed urologist, the steps above should be repeated from the beginning.

Tomb of Hafez, Persian Poet (1315-1390), Shiraz, Iran

**Thank you for your attention!**