

Long Urethral Stricture in Elderly


RUD-TJH Experiences

Jalil Hosseini

Professor of Urology
Reconstructive Urology Dept.
Tajrish Hospital, Tehran – Iran

President, A-P SRUAS
Past President, UAA

Honorary Member, EAU
Past President, IUA



Reconstructive Urology Shahid Beheshti Medical University

SBMU

TAJRISH HOSPITAL

FOUNDED IN 1958

RUD, TAJRISH

24 years experience

Long Urethral Stricture in Elderly

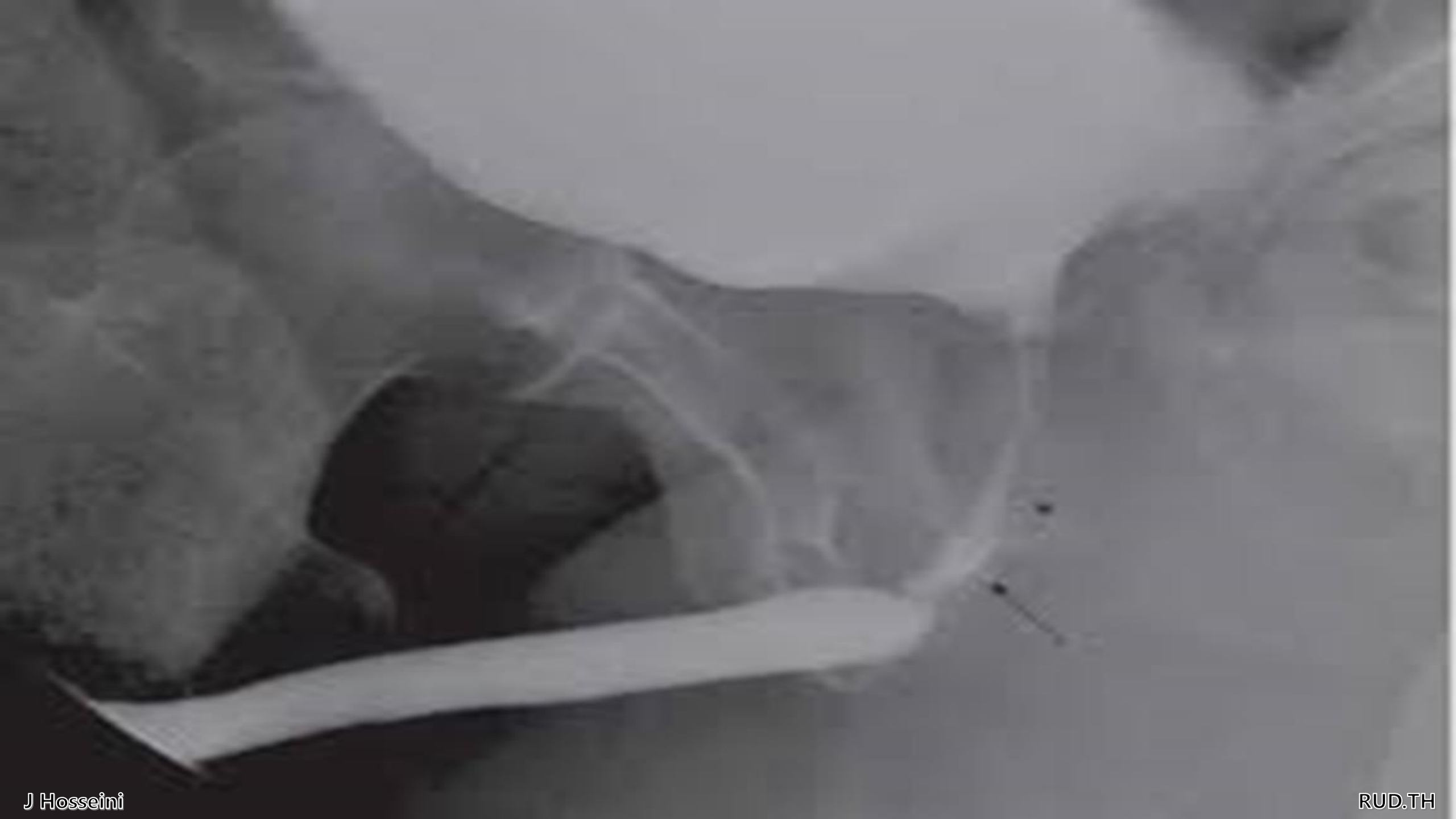- **History:**

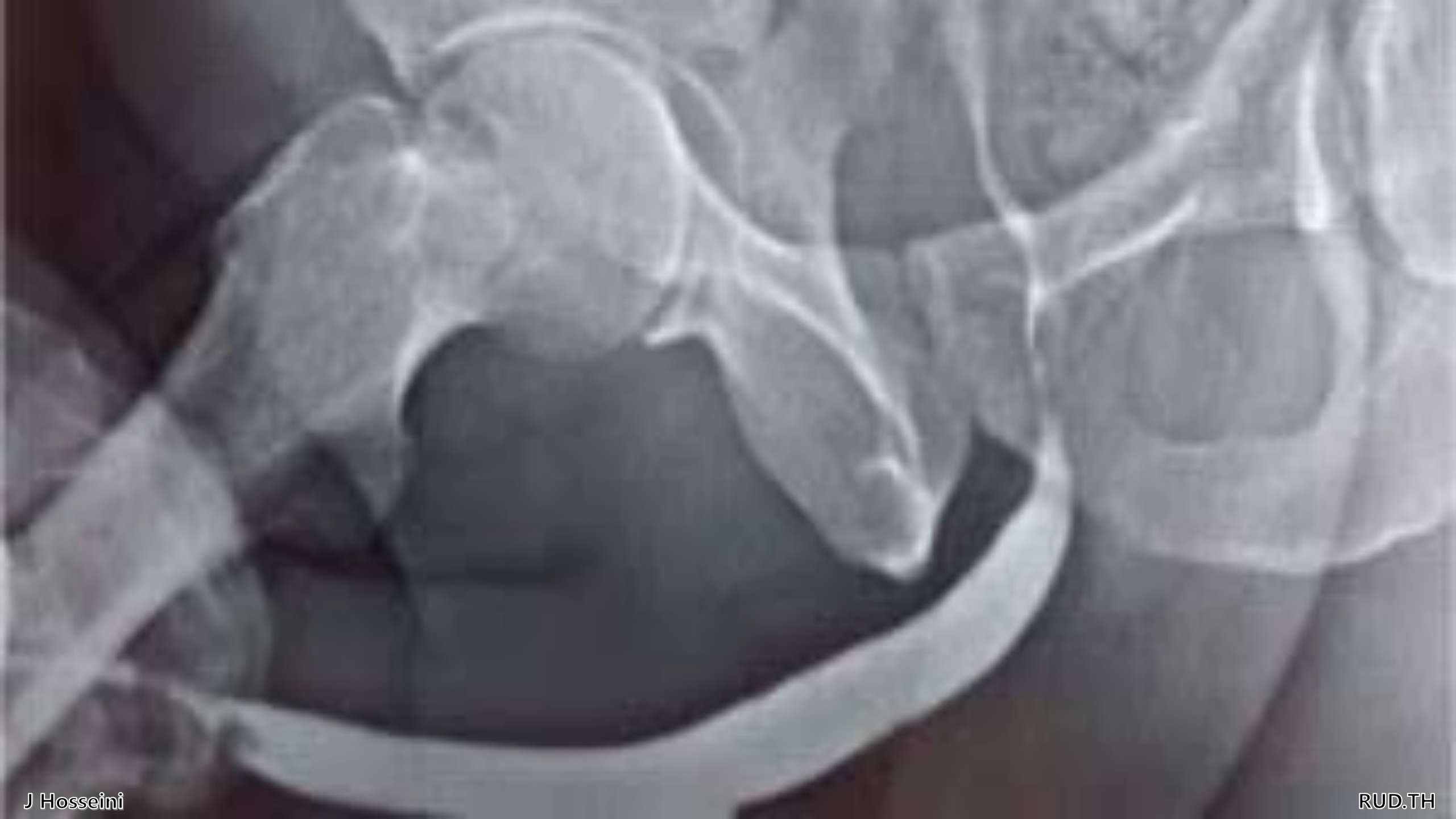- **90 years Old,**
- **Long anterior U.Stricture**
- **Several Dilatation, Comorbid**
- **Every 3 month in Operation Room with Anesthesia**

Long Urethral Stricture in Elderly

- **History :**

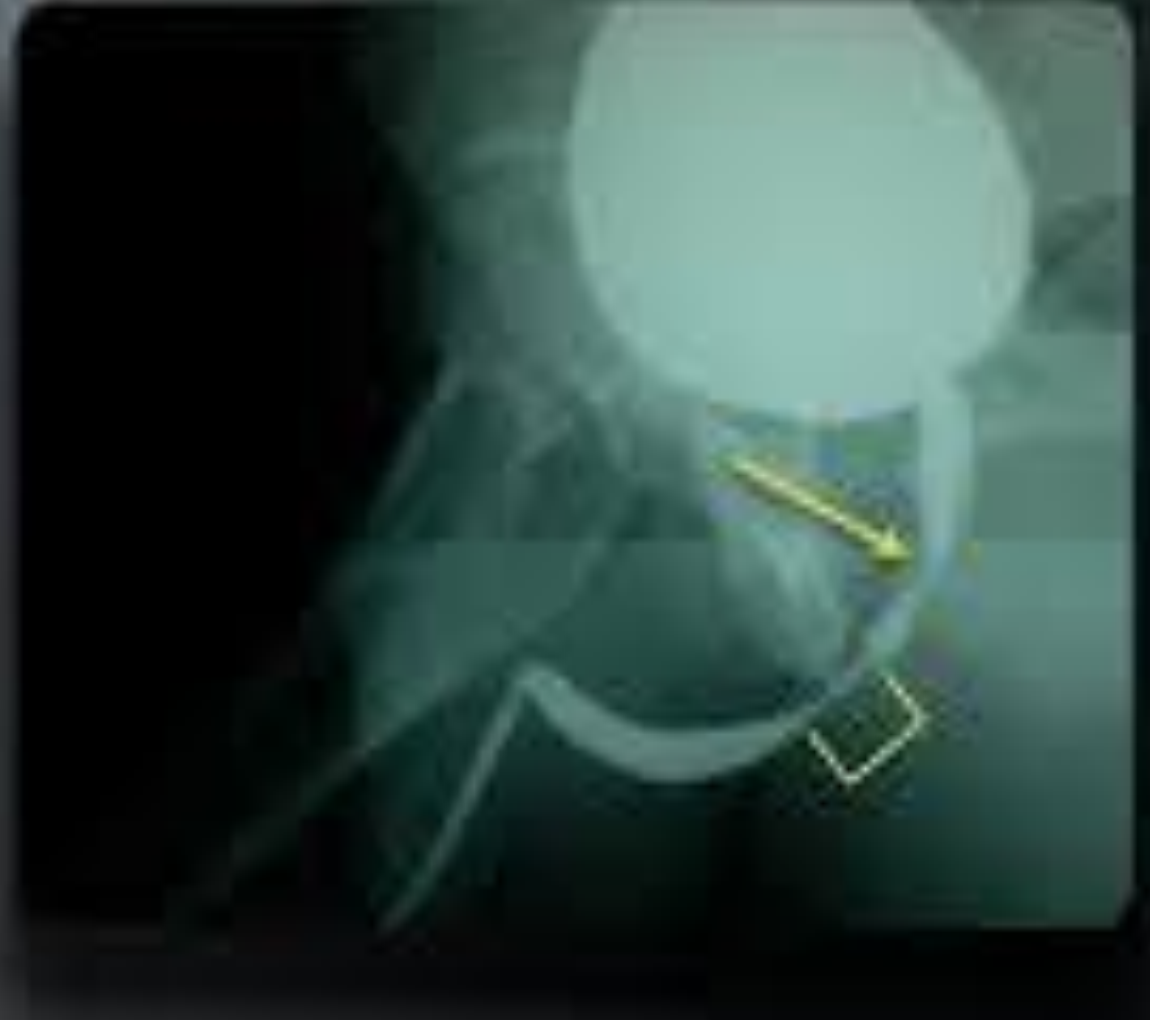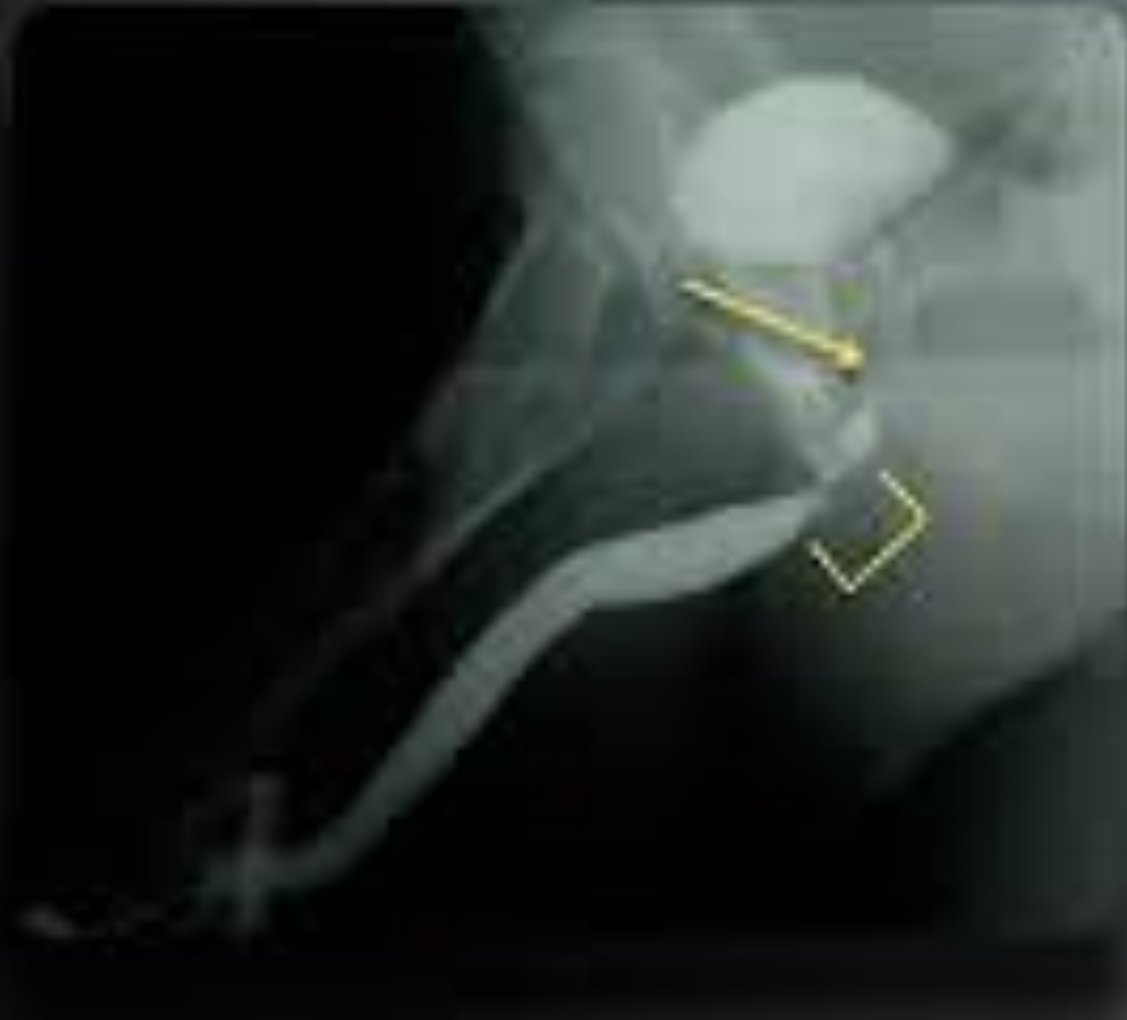- **85 Years Old**
- **Prostatectomy(or TURP)**
- **Membranous Stricture**
- **Several Dilatation**
- **Every 2 month in Operation Room with Anesthesia**



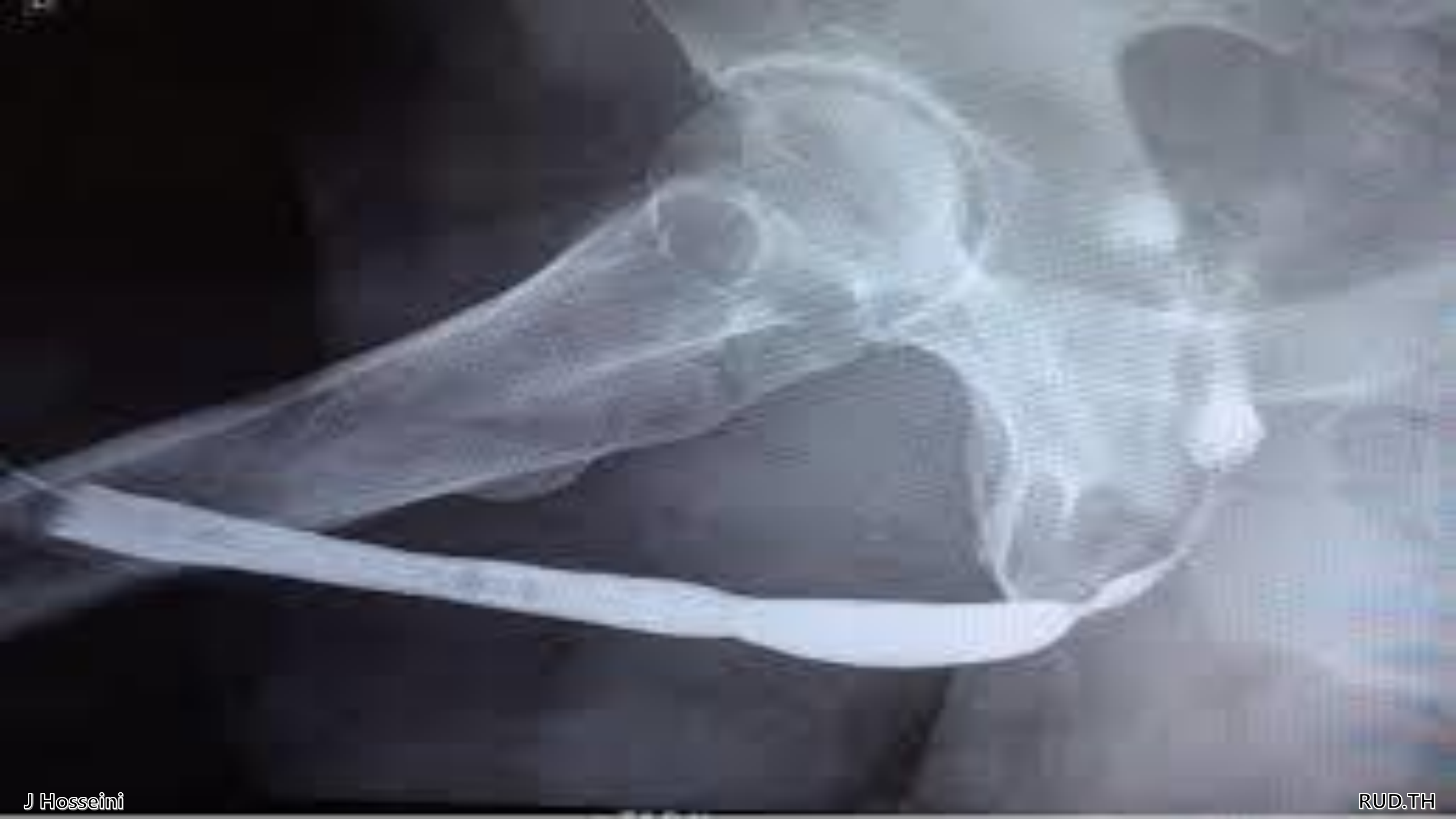

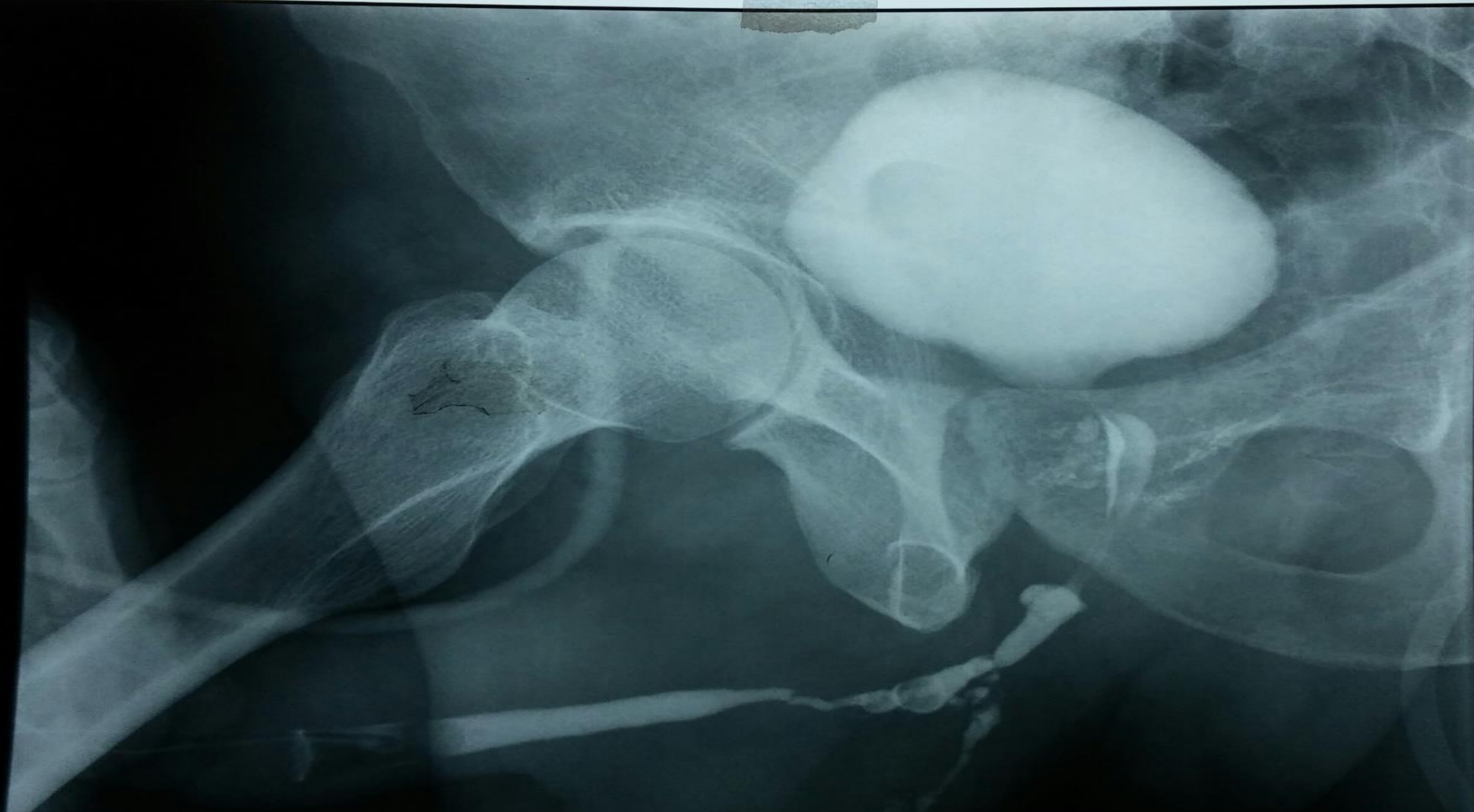Recurrent membranous
stricture after radiation





Bulbar and Membranous Stricture





Kushki, Tahmas
8/38

Da: 10/24/2012
Ti: 3:36:58 PM

CLASSIC CR

SE: 1
IM: 1

BILAT FROG

2cm/LE

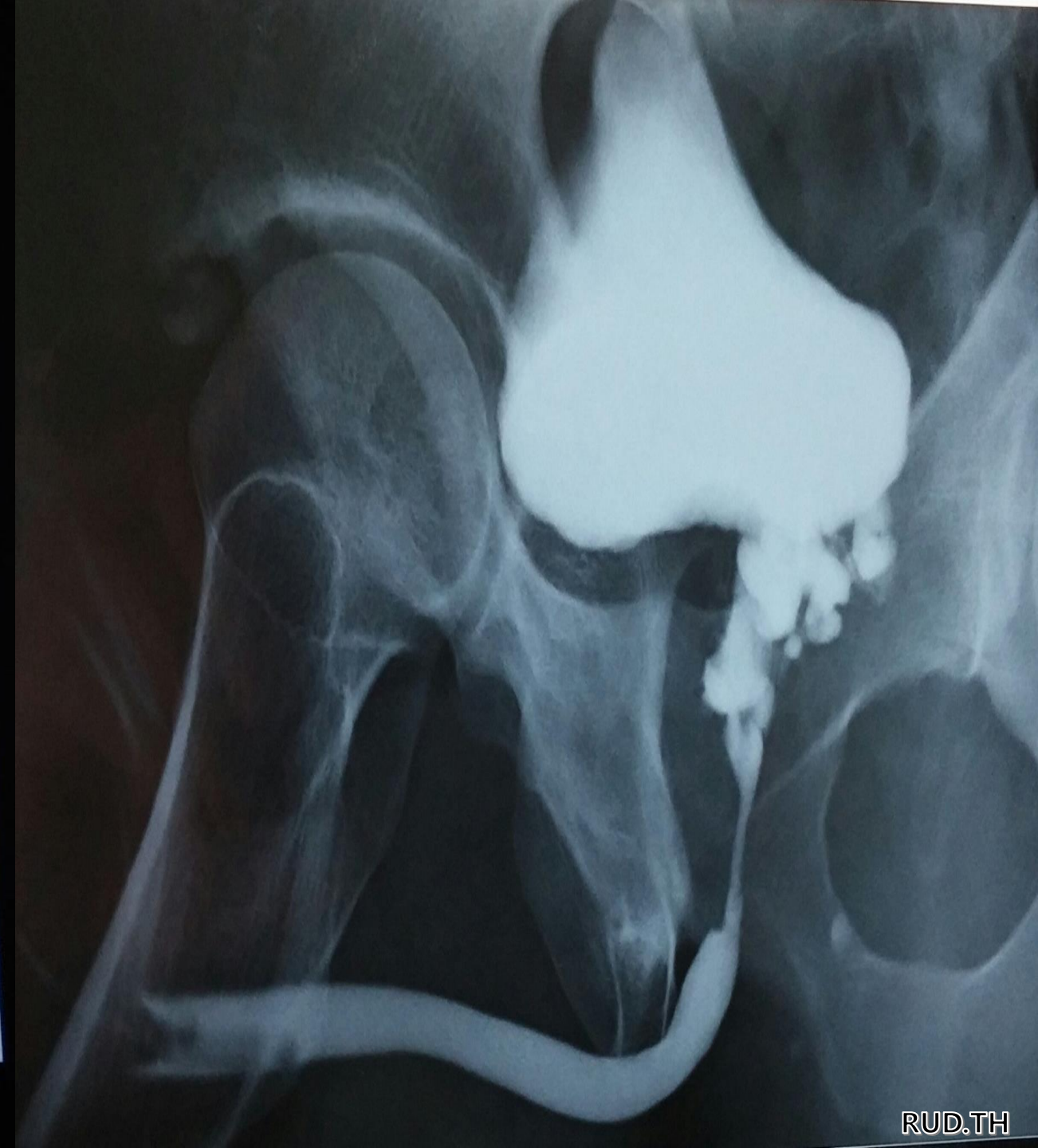
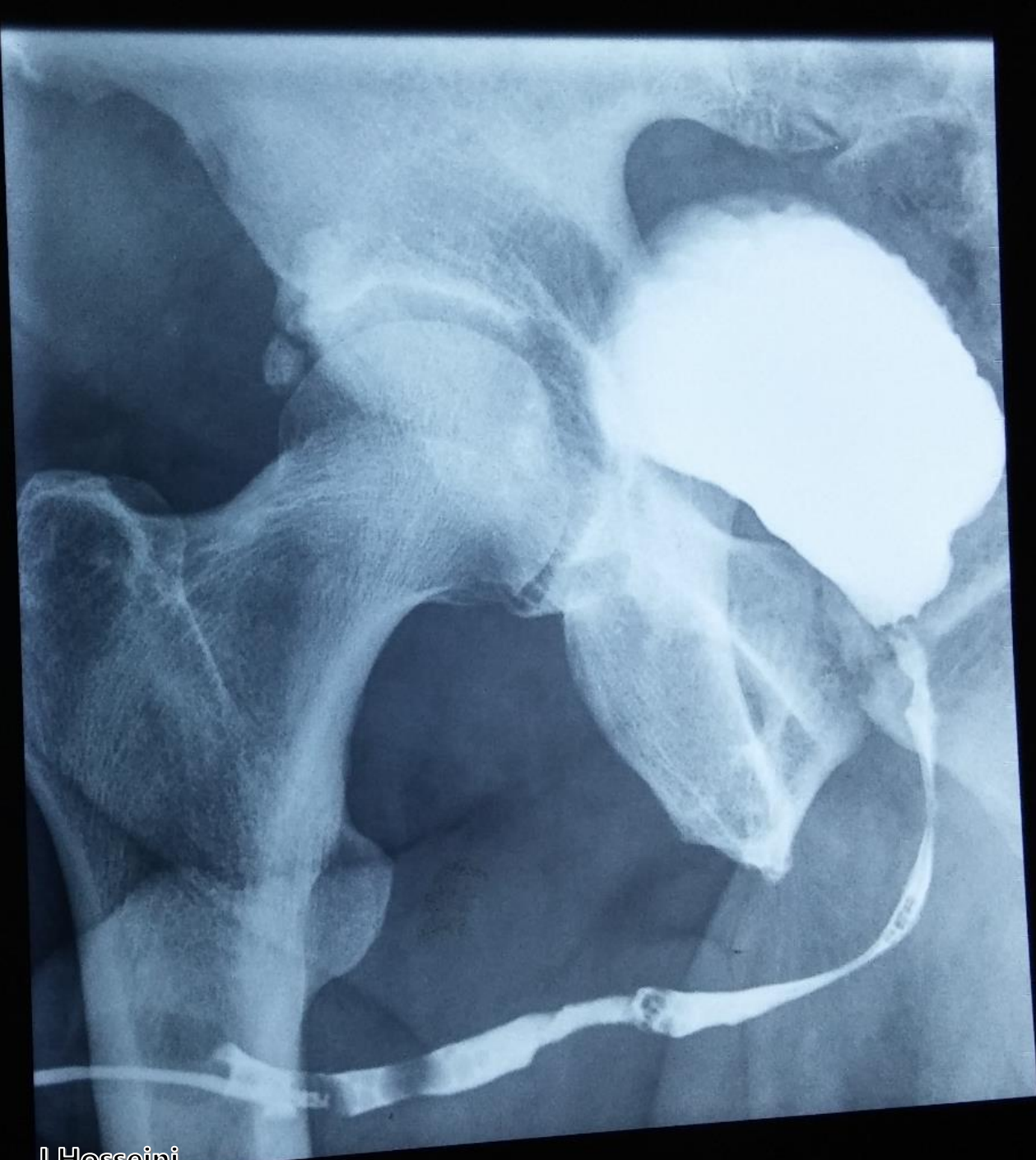
RUG1

W: 4096 C: 2048
Zoom 1.19
CR

3020 x 2400

DR.GOLESTANHA IMAGING CENTER RUD.TH

J Hosseini




W: 4096 C: 2048
Zoom 1.24
CR
2048 x 2048
DR.GOLESTANHA IMAGING CENTER



RUG2

W: 4096 C: 2048
Zoom 1.09
CR
2048 x 2048
DR.GOLESTANHA IMAGING CENTER



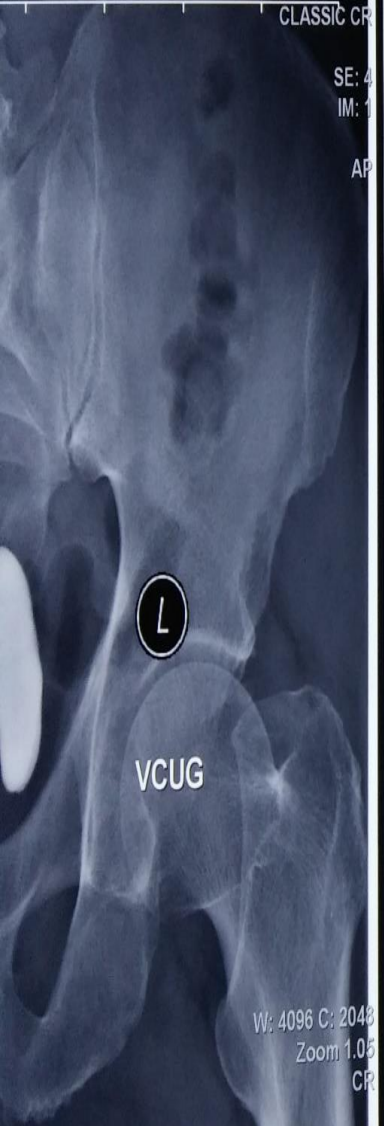
RUG3

Kushki, Tahmas
8/38
Date: 10/24/2012
Time: 3:42:13 PM

DR.GOLESTANHA IMAGING CENTER
CLASSIC CR
SE:
IM:
BILAT FRO

CLASSIC CR
SE: 4
IM: 1
AP

Rohinezhad, Hasan
11=18
Da: 1/21/2014
Ti: 9:29:49 PM

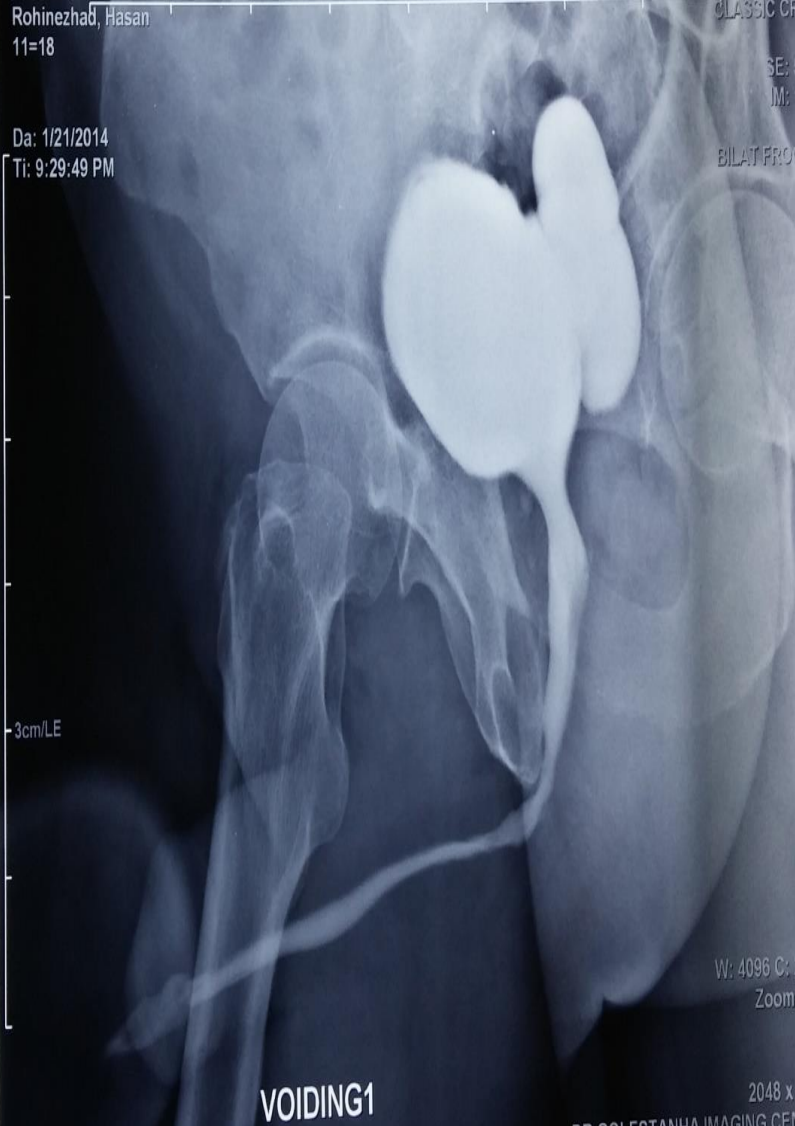


L

VCUG

3cm/LE

CLASSIC CR
SE: 5
IM: 1
BILAT FRO



VOIDING1

2cm/LE

W: 4096 C: 2048
Zoom
2048 x 2048
DR.GOLESTANHA IMAGING CENTER

W: 4096 C: 2048
Zoom 1.24
CR
3020 x 2400
DR.GOLESTANHA IMAGING CENTER

J Hosseini
2048 x 2500
DR.GOLESTANHA IMAGING CENTER

DR.GOLESTANHA IMAGING CENTER
RUD.TH

Long Urethral Stricture in Elderly

- **History :**

- 85 Years old 90 Years Old

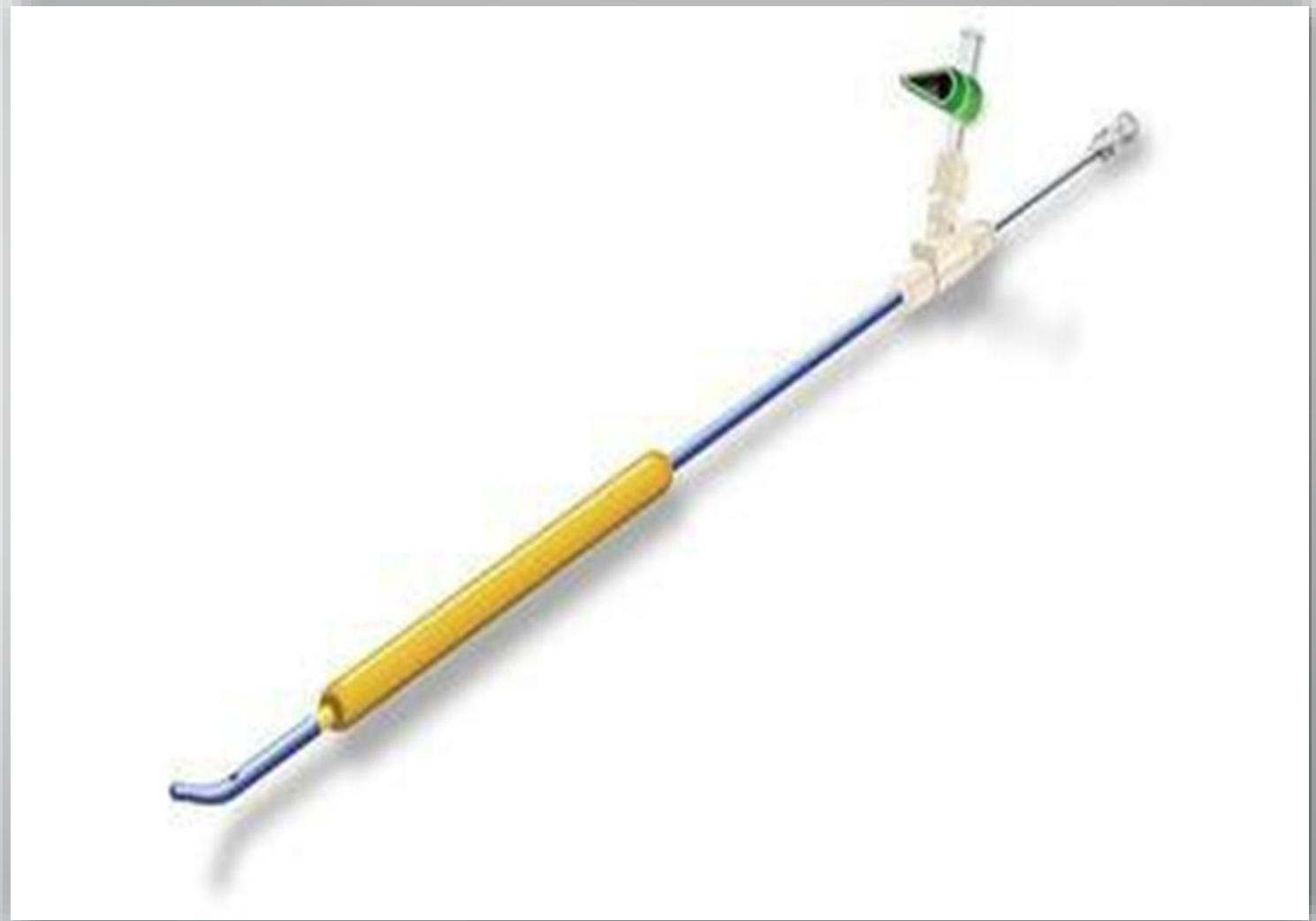
- Many operation room admit

- **How many time do you want to repeat**

Hydraulic Urethral Dilatation

- One of the effective therapies for urethral stenosis is the use of a urethral hydraulic catheter.
- In order to take advantage of the optimal and appropriate therapeutic response
- With proper use of this catheter, the patient will not require frequent intraoperative delivery, anesthetic tolerance and recurrent dilation.
- The patients need Primary urethral dilatation to accommodate HUD
- Primary education is done at the clinic in the presence of the urologist

HUD catheter



Technical Points

First, remove the catheter from the compartment and clean it with a sterile serum.

- Before inserting the catheter, it is important to use the lubricants

- The catheter should be inserted into the urethra with its tilting upwards and note that the entire yellow part of the catheter is inside the urethra.
- It is recommended to use distilled water to fill the balloon around the catheter and fill the balloon to the extent that the patient feels pain (4 to 8 cc).
- Depending on the urologist's advice, the duration of the catheter in the urethra will be between 4 and 6 hours.
- After using the catheter, the catheter is thoroughly washed with a clean wash, sterilized in a sterile cleanser and kept in a container in which a single formalin tablet is inserted.
.
- At the time of re-use with the prescribed urologist, the steps above should be repeated from the beginning.

Tomb of Hafez, Persian Poet (1315-1390), Shiraz, Iran

Thank you for your attention!